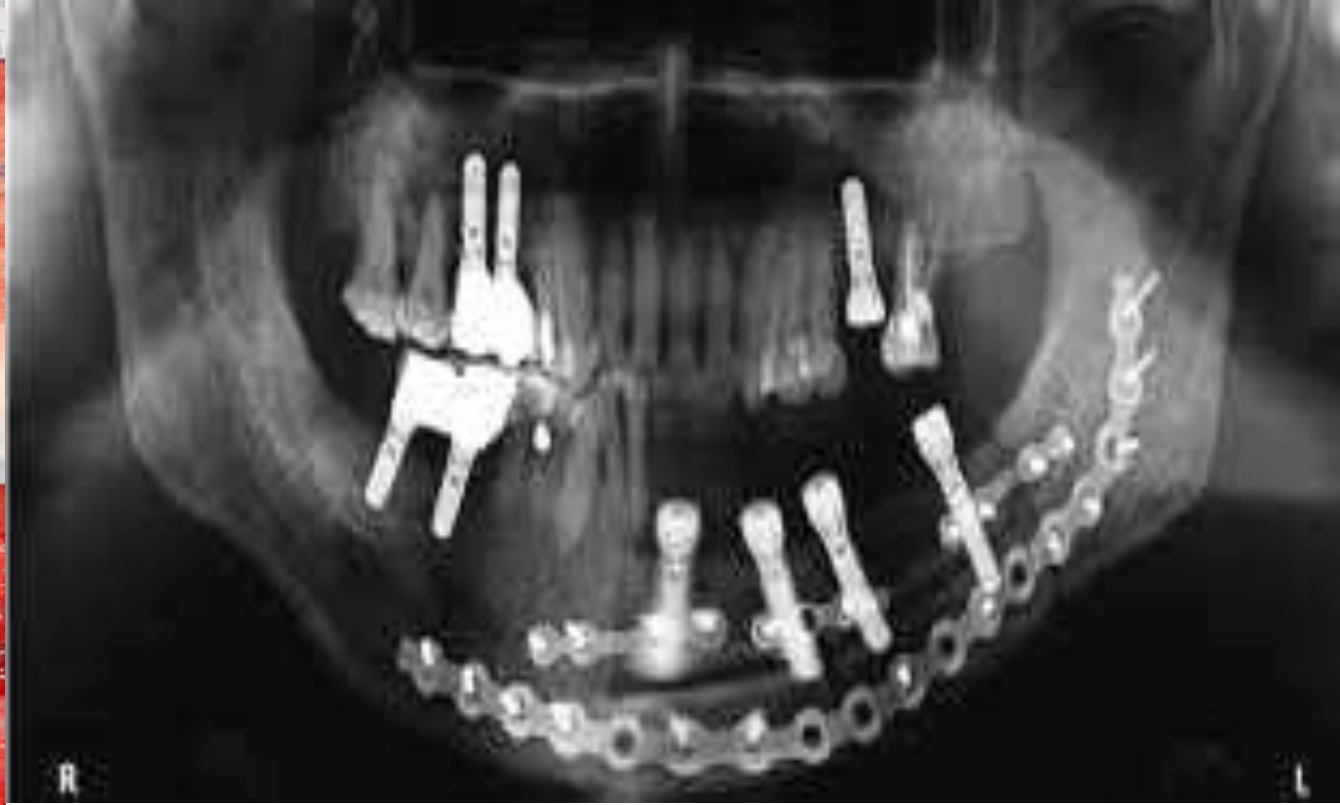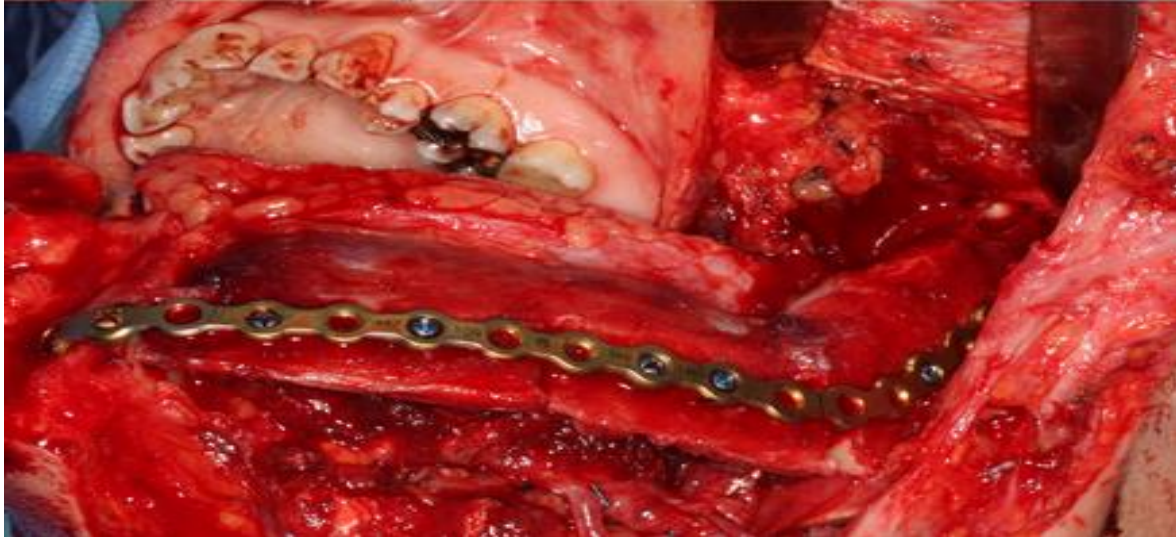
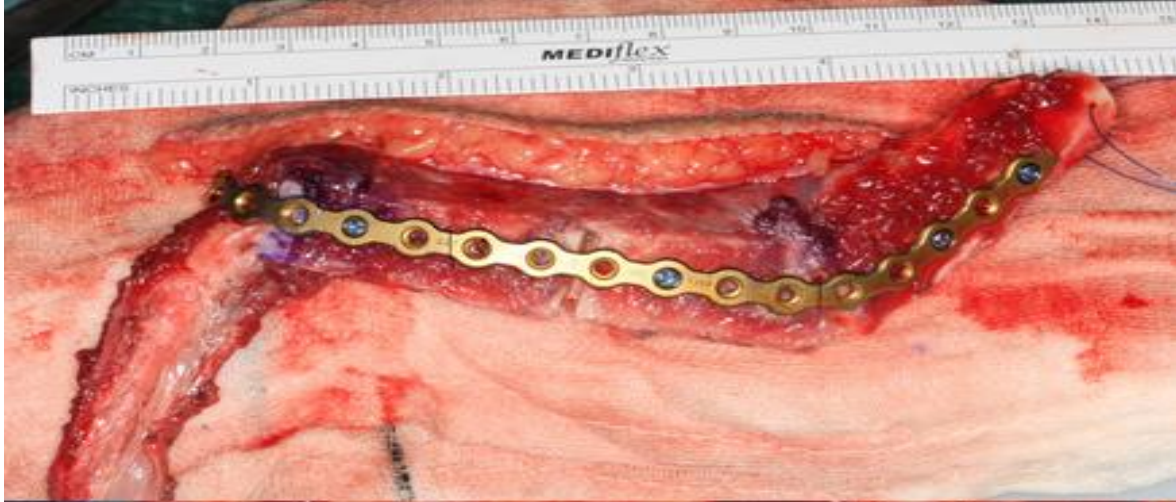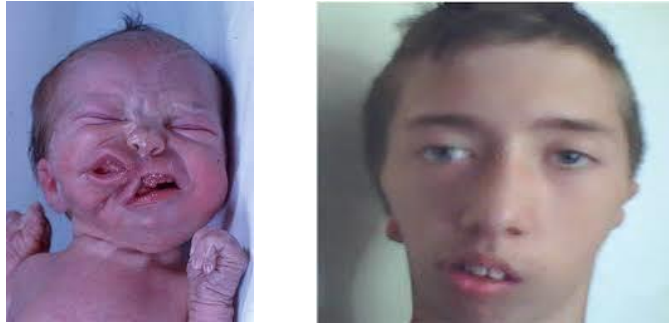


Principles of Reconstructive Surgery of Defects of the Jaws

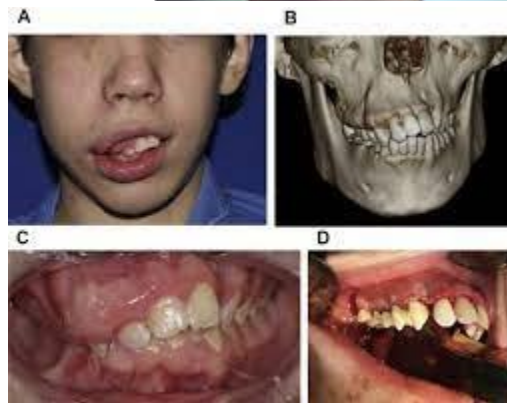
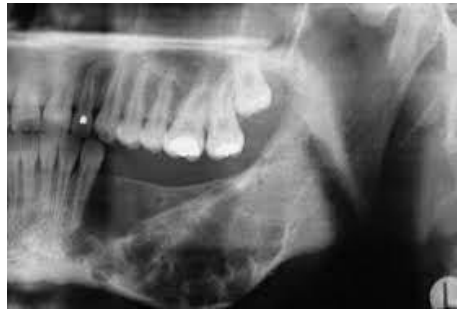
Defects of the facial bones, especially the jaws, have a variety of causes:

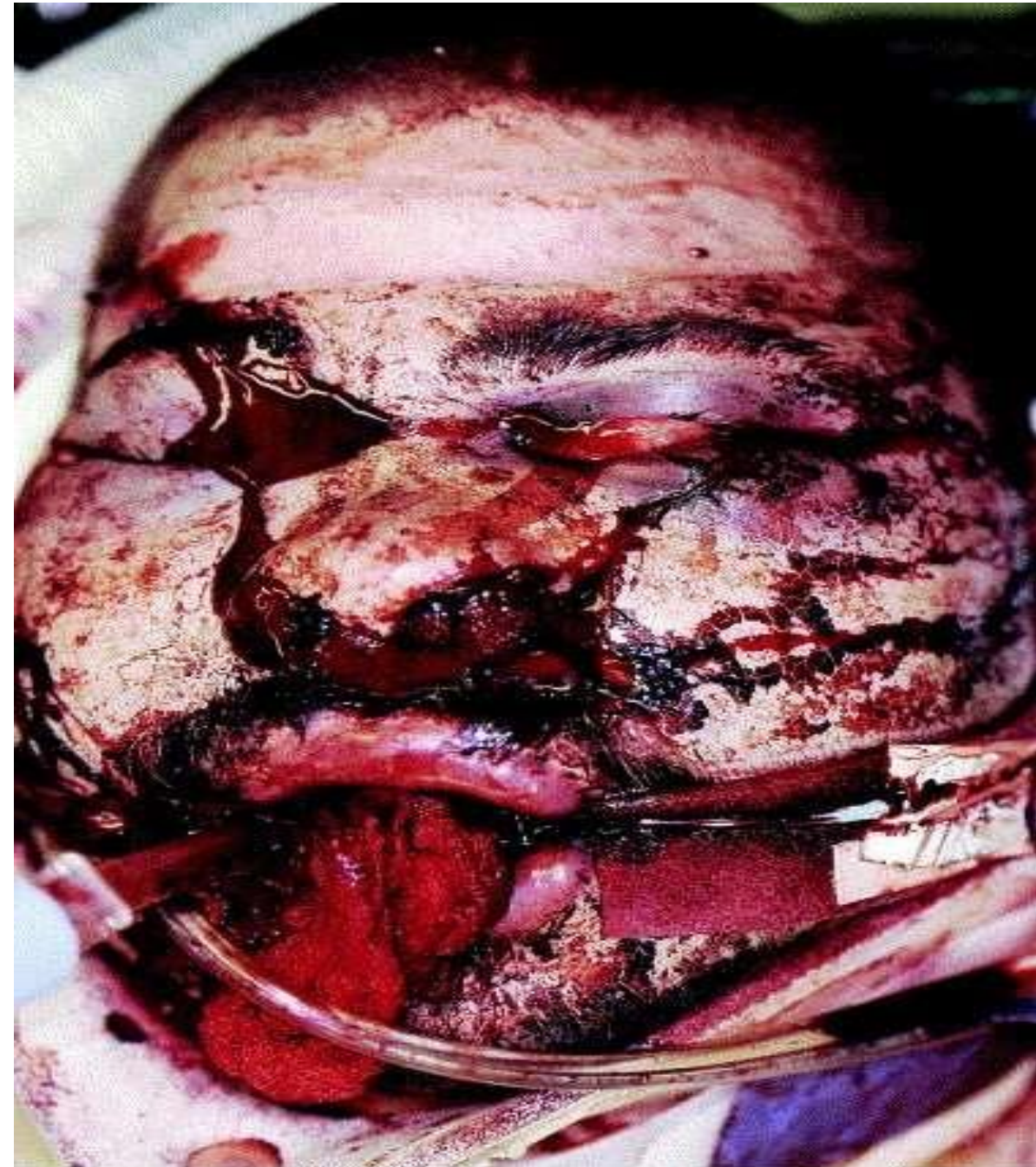
1. Congenital



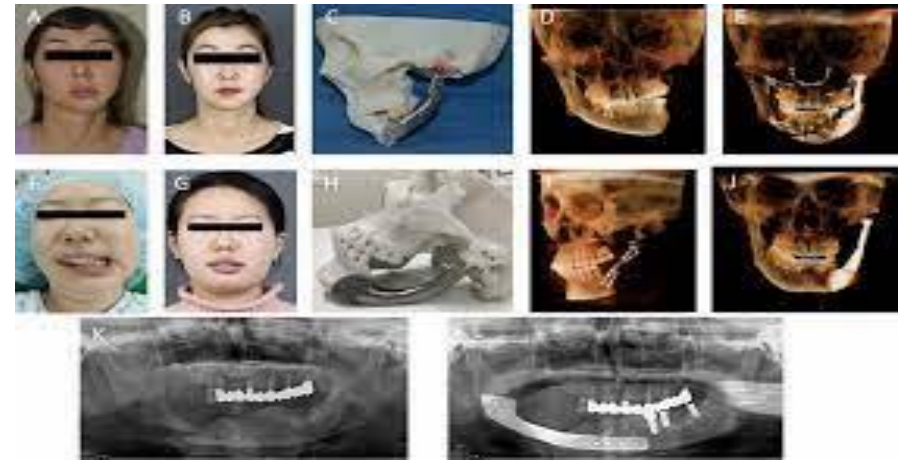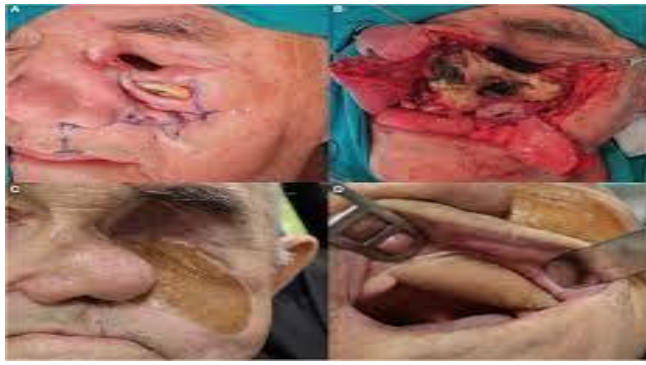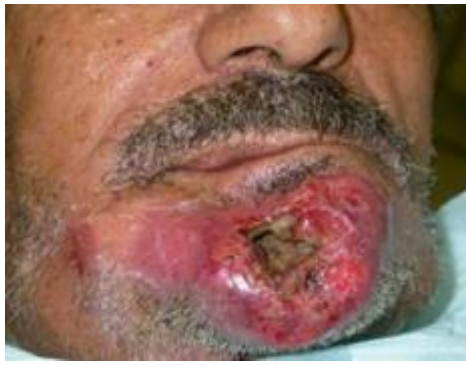2. Pathologic



3. Trauma related



4. Infectious



5. Acquired

The size of the defects that are commonly reconstructed in the oral and maxillofacial region varies considerably from **small alveolar clefts** to **mandibulectomy defects**. Each defect poses a unique set of problems that reconstructive surgical intervention must address.

In an **“ideal reconstruction”** the missing tissue is replaced with an identical substitute. This ideal is difficult, and usually impossible, to achieve. Without being able to perform an “ideal reconstruction” in every case, the surgeon is left with options along the reconstructive ladder.

This graduated range of reconstructive choices includes healing by **secondary intention**, **primary closure**, **delayed closure**, **split thickness skin graft**, **full thickness skin graft**, **tissue expansion**, **random pattern flap**, **pedicled flap**, and **free tissue transfer**.

The reconstructive/rehabilitative technique chosen, is tailored in each case, and may depend significantly on surgeon preference and expertise. It must account for the **complexity of the defect**, as well as for **patient factors**. Comorbid conditions have to be included in the **risks-benefits analysis**. **Free tissue reconstruction can add considerable time to the operation**, increasing the **risk of general anesthesia**, with a higher potential for postoperative complications. Certain patients with significant comorbidities would benefit from a less taxing reconstructive approach.

Goals of Reconstruction

- Restoration of function
- Restoration of cervicofacial symmetry and form
- Creation of barriers between cavities and spaces in the head and neck that should not communicate
- Facial reanimation
- Dental rehabilitation
- Return of sensation

When an osseous structure is defective in size, shape, position, or amount, reconstructive surgery can replace the defective structure. The tissue most commonly used to replace lost osseous tissue is bone. Bone grafting has been attempted for centuries with varying degrees of success.

Biologic Basis of Bone Reconstruction :

Bone graft healing is a sequential process involving inflammation, revascularization, osteogenesis, remodeling, and incorporation into the host skeleton to form a mechanically efficient structure.

A tissue that is transplanted and expected to become a part of the host to which it is transplanted is **known as a graft**. Several **types of grafts are available to the surgeon**.

A basic understanding of how a bone heals when grafted from one place to another in the same individual (i.e., autotransplantation) is necessary to understand the benefits of the various types of bone grafts available. The healing of bone and bone grafts is unique among connective tissues because new bone formation arises from tissue regeneration rather than from simple tissue repair with scar formation. This healing therefore requires the element of cellular proliferation (i.e., osteoblasts) and the element of collagen synthesis. When bone is transplanted from one area of the body to another, several processes become active during the incorporation of the graft.

Two-Phase Theory of Osteogenesis

Two basic processes occur on transplanting bone from one area to another in the same individual.

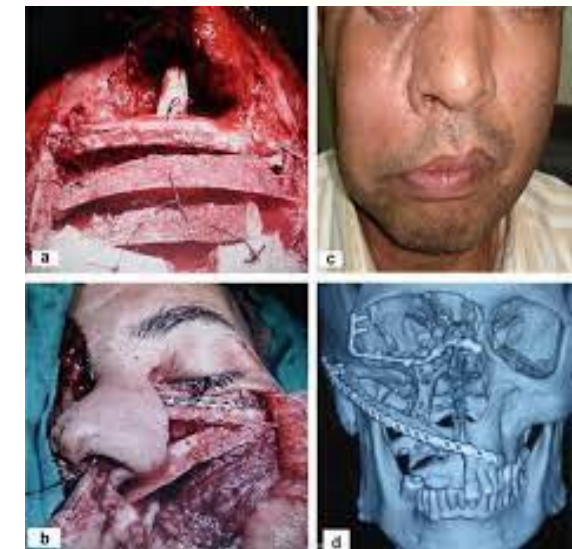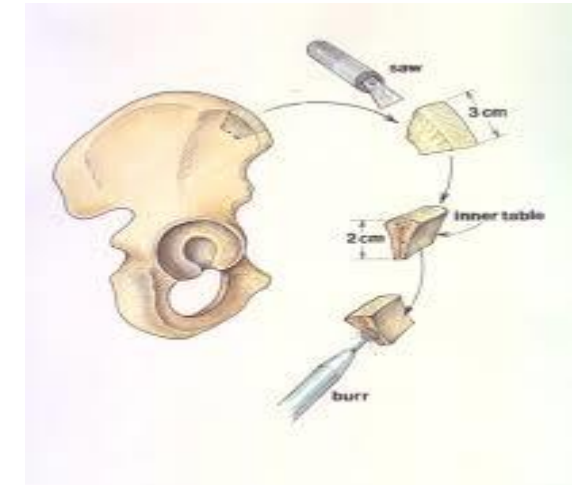
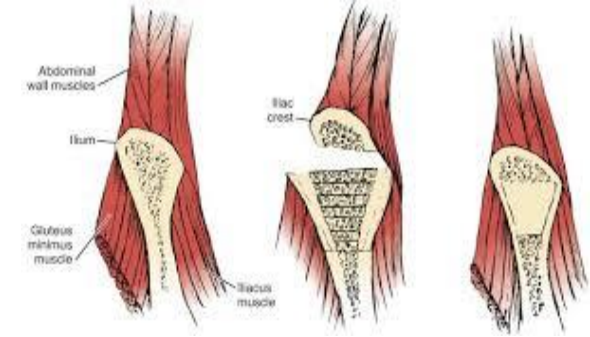
The first process that leads to bone regeneration arises **from transplanted graft cells** initially from transplanted cells in the graft that proliferate and form new osteoid. The amount of bone regeneration during **this phase depends on the number of transplanted bone cells that survive during the grafting procedure.**

Obviously, when the graft is **first removed from the body**, the blood supply has been severed. Thus the cells in the bone graft depend on **diffusion of nutrients from the surrounding graft bed (i.e., the area where the graft is placed) for survival.**

A considerable amount of cell death occurs during the grafting procedure, and **this first phase of bone regeneration may not lead to an impressive amount of bone regeneration when considered alone. Still, this phase is responsible for the formation of most of the new bone.**

The more viable cells that can be successfully transplanted with the graft, the more bone that will form. **The graft bed also undergoes changes that lead to a second phase of bone regeneration beginning in the second week.** Intense angiogenesis and fibroblastic proliferation from the graft bed begin after grafting, and **osteogenesis from host connective tissues soon begins.**

Fibroblasts and other mesenchymal cells differentiate into osteoblasts and begin to lay down new bone.



Evidence shows that a protein (or proteins) found in the bone induce these reactions in the surrounding soft tissues of the graft bed. This second phase is also responsible for the orderly incorporation of the graft into the host bed with continued resorption, replacement, and remodeling.

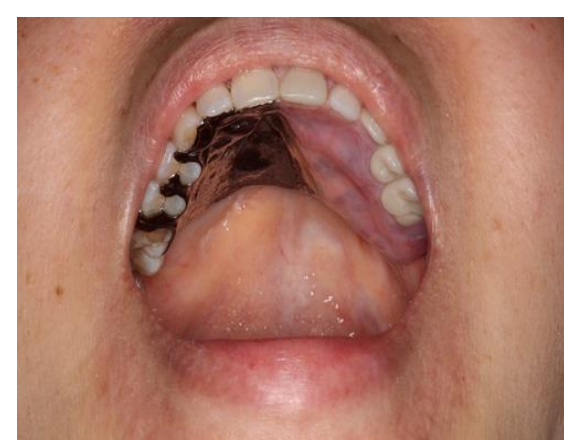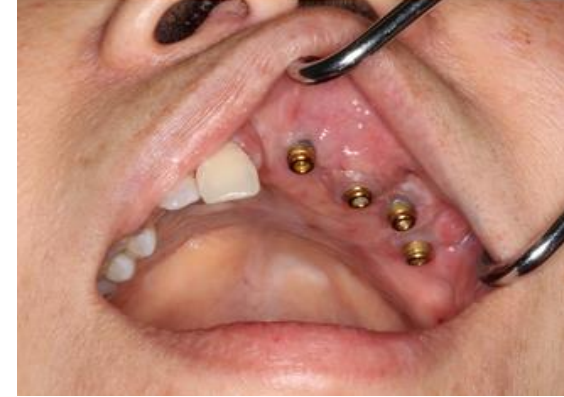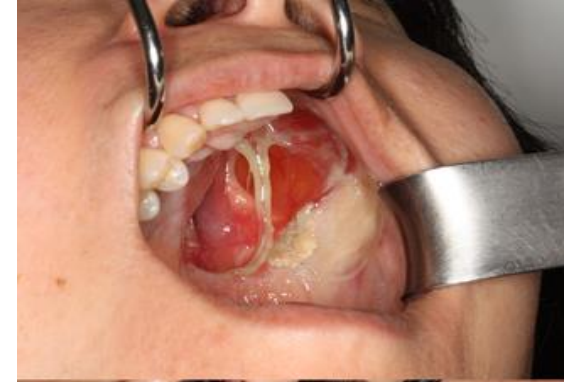Immune Response

When a tissue is transplanted from **one site to another in the same individual**, immunologic complications **usually do not occur**. The immune system is not triggered because the tissue is recognized as **"self."** However, when a tissue is transplanted from **one individual to another or from one species to another**, the immune system may present a **formidable obstacle to the success of the grafting procedure**.

If the graft is recognized as a foreign substance by the host, it will mount an intense response in an **attempt to destroy the graft**. The type of response the immune system mounts against **"foreign"** grafts is primarily a cell-mediated response by **T lymphocytes**. **The response may not occur immediately**, however, and in the early period the incorporation of a bone graft into the host may appear to **be progressing normally**. The length of this latent period **depends on** the similarity between the **host and the recipient**.

The more similar they are (antigenically), the longer an immunologic reaction may take to appear.

This type of immunologic reaction is the most common reason for rejection of hearts, kidneys, and other organs transplanted to another individual.



Tissue typing procedures, in which a donor and recipient are genetically compared for similarities before transplantation, are currently common practice for organ transplantation but never for bone grafts.

Because of the immunologic rejection of transplants **between individuals** or **between species**, methods have been devised to **improve the success of grafting procedures in these instances.**

Two basic approaches **are used clinically:**

The first is the suppression of the host individual's immune response. **Immunosuppression with various medications is most commonly used in organ transplant patients.**

This approach is not used routinely in oral and maxillofacial surgical bone grafting procedures because of the potential complications from immunosuppression.

Another approach that has been used extensively in oral and maxillofacial surgical procedures is the **alteration of the antigenicity of the graft so that the host's immune response will not be stimulated.**

Several methods of treating grafts have been used, **including boiling, deproteinization**, use of **thimerosal (Merthiolate)**, **freezing, freeze-drying, irradiation**, and **dry heating.**

All of these methods, potentially helpful for **use in bone grafts**, are **obviously not helpful in organ transplants.**

Types of Grafts

Several types of bone grafts are available for use in reconstructive surgery. A useful classification categorizes the bone grafts according to their origin and thus their potential to induce an immunologic response. Because of their origins and the preparations used to help avoid an intense immune response, the grafts have different qualities and indications for use.

Autogenous Grafts

Also known as autografts or self-grafts, autogenous grafts are composed of tissues from the same individual. Fresh autogenous bone is the most ideal bone graft material. The autogenous graft is unique among bone grafts in that it is the only type of bone graft to supply living, immunocompatible bone cells essential to phase I osteogenesis. The larger number of living cells that are transplanted, the more osseous tissue that will be produced. They are two types **avascular** and **vascular bone grafts**

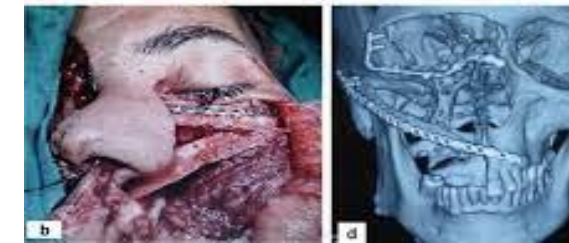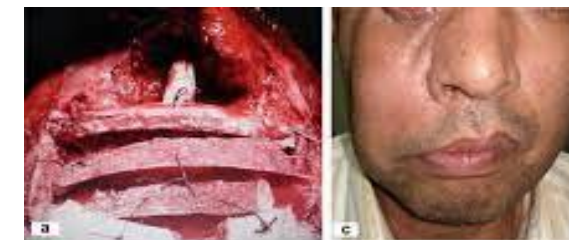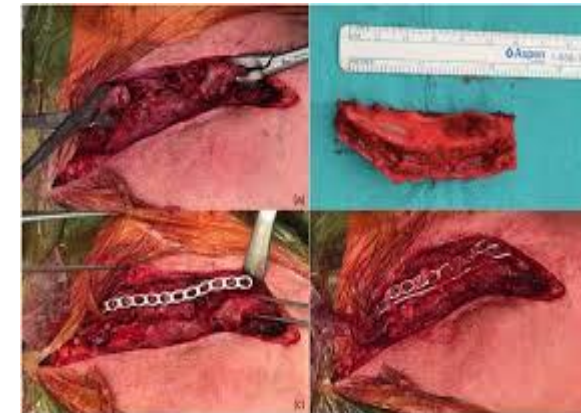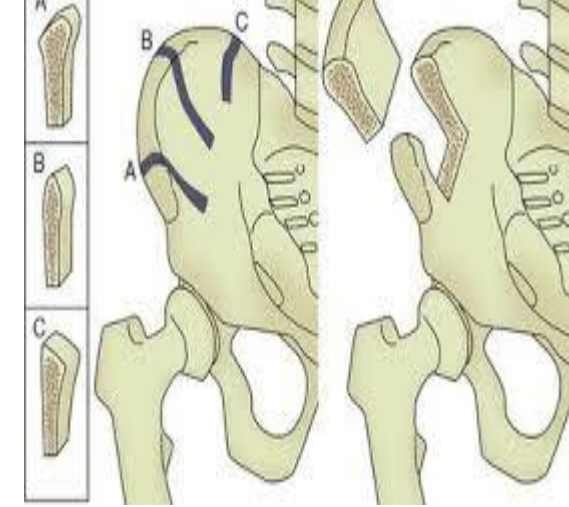
Autogenous bone is the type used most frequently in oral and maxillofacial surgery.

The bone can be obtained from a host of sites in the body and can be taken in several forms. **Block grafts are solid pieces of cortical bone and underlying cancellous bone.**

The iliac crest is often used as a source for this type of graft. The entire thickness of the ilium can be obtained, or the ilium can be split to obtain a thinner piece of block graft.

Ribs also constitute a form of block graft. Particulate marrow and cancellous bone grafts are obtained by harvesting the medullary bone and the associated endosteum and hematopoietic marrow.

Particulate marrow and cancellous bone grafts produce the greatest concentration of osteogenic cells, and because of the particulate nature, more cells survive transplantation because of the access they have to nutrients in the surrounding graft bed. The most common site for the procurement of this **type of graft is the ilium.**



The autogenous bone may also be transplanted while maintaining the blood supply to the graft. Two methods can accomplish this: The first involves the transfer of a bone graft pedicled to a muscular (or muscular and skin) pedicle.

The bone is not stripped of its soft tissue pedicle, preserving some blood supply to the bone graft. Thus the number of surviving osteogenic cells is potentially great.

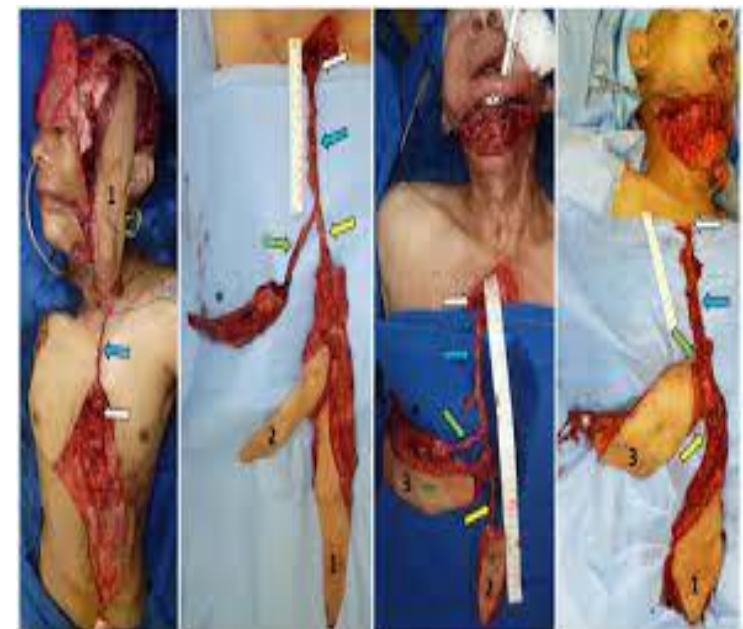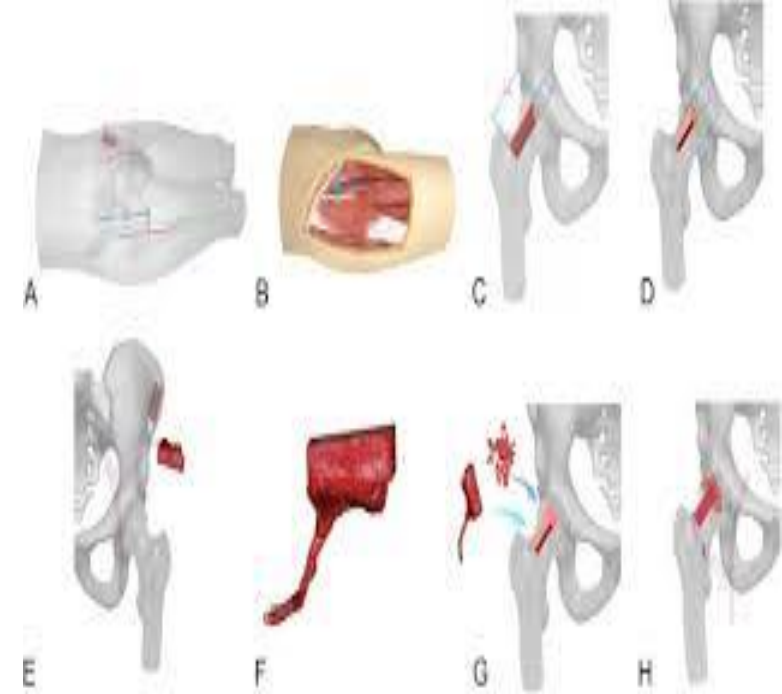
An example of this type of autogenous graft is a segment of the clavicle transferred to the mandible, pedicled to the sternocleidomastoid muscle.

The second method by which autogenous bone can be transplanted without losing blood supply is by the use of microsurgical techniques.

A block of ilium, tibia, rib, or other suitable bone is removed along with the overlying soft tissues after dissecting free an artery and a vein that supply the tissue. An artery and a vein are also prepared in the recipient bed. Once the bone graft is secured in place, the artery and veins are reconnected using microvascular anastomoses. In this way the blood supply to the bone graft is restored.

Both of these types of autogenous grafts are known as composite grafts because they contain soft tissue and osseous elements. **The first type described**, in which the bone maintains a muscular origin, is a pedicled composite graft. The pedicle is the soft tissue remaining on it, which supplies the vasculature.

The second type of composite graft is a free composite graft, meaning that it is totally removed from the body and immediately replaced, and its blood supply is restored by reconnection of blood vessels.



Although these types of grafts may seem ideal, they have some shortcomings when used to restore defects of the jaws. Because the soft tissues attached to the bone graft maintain the blood supply, there can be minimal stripping of the soft tissue from the graft during procurement and placement. Thus the size and shape of the graft cannot be altered to any significant degree. Frequently, inadequate bulk of bone is provided when these grafts are used to restore mandibular continuity defects.

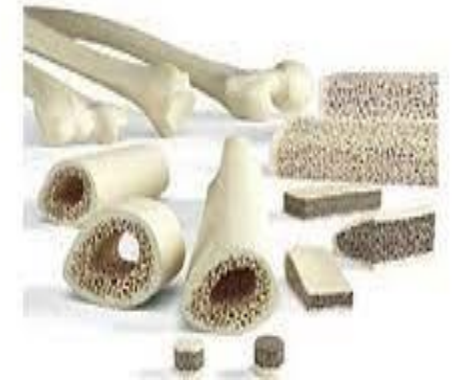Another problem is the morbidity to the donor site. Instead of just removing osseous tissue, soft tissues are also removed with composite grafts, which cause greater functional and cosmetic defects.

The advantages of autogenous bone are that it provides osteogenic cells for phase I bone formation, and no immunologic response occurs.

A disadvantage is that this procedure necessitates another site of operation for procurement of the graft.

Allogeneic Grafts

Also known as allografts or homografts, allogeneic grafts are grafts taken from another individual of the same species. Because the individuals are usually genetically dissimilar, treating the graft to reduce the antigenicity is routinely accomplished. Today, the most commonly used allogeneic bone is freeze-dried. All of these treatments destroy any remaining osteogenic cells in the graft, and therefore allogeneic bone grafts cannot participate in phase 1 osteogenesis.



The assistance of these grafts to **osteogenesis is purely passive**; they offer a hard tissue matrix for phase II induction.

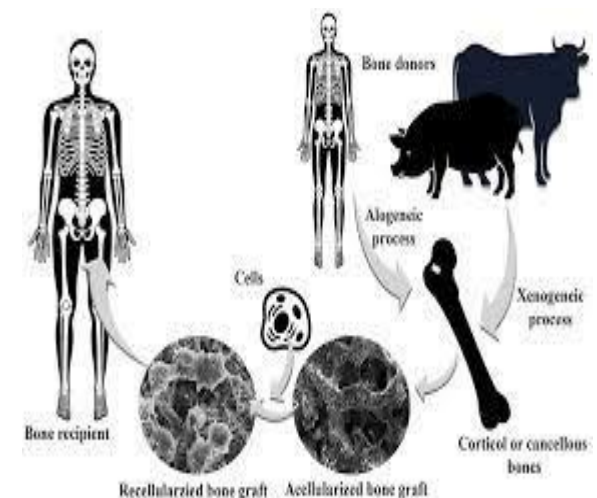
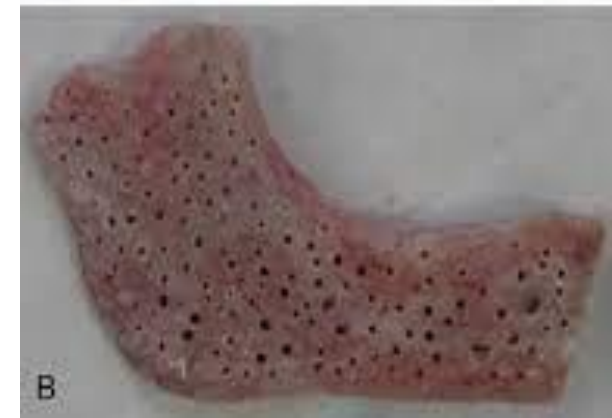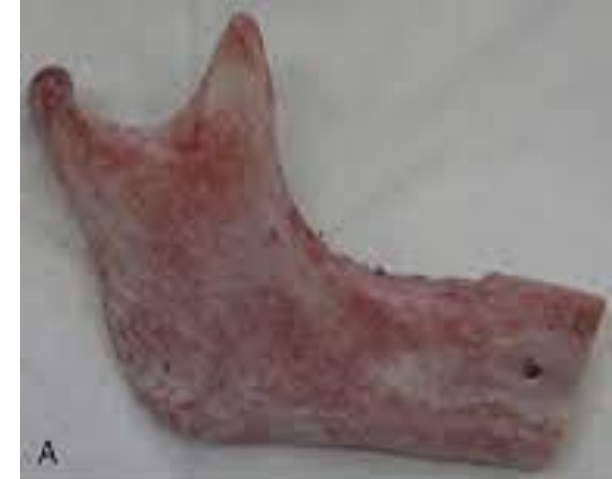Thus the host must produce all of the essential elements in the graft bed for the allogeneic bone graft to become resorbed and replaced. Obviously, the health of the graft bed is much more important in this set of circumstances than it is if autogenous bone were to be used.

Advantages are that allogeneic grafts do not require another site of operation in the host and that a similar bone or a bone of similar shape to that being replaced can be obtained (e.g., an **allogeneic mandible can be used for reconstruction of a mandibulectomy defect**). The **disadvantage** is that an allogeneic graft does not provide **viable cells for phase I osteogenesis**.

Xenogeneic Grafts

Also known as **xenografts or heterografts**, xenogeneic grafts are taken from **one species and grafted to another**.

The **antigenic dissimilarity** of these grafts is greater than with allogeneic bone. The organic matrix of **xenogeneic bone is antigenically dissimilar to that of human bone**, and therefore the **graft must be treated more vigorously to prevent rapid rejection of the graft**. Bone grafts of this variety are rarely used in major oral and maxillofacial surgical procedures.



Advantages are that xenografts do not require another site of operation in the host, and a large quantity of bone can be obtained. **Disadvantages** are that xenografts do not provide viable cells for phase I osteogenesis and must be rigorously treated to reduce antigenicity.

Osteoinduction, Osteoconduction and Osteogenesis

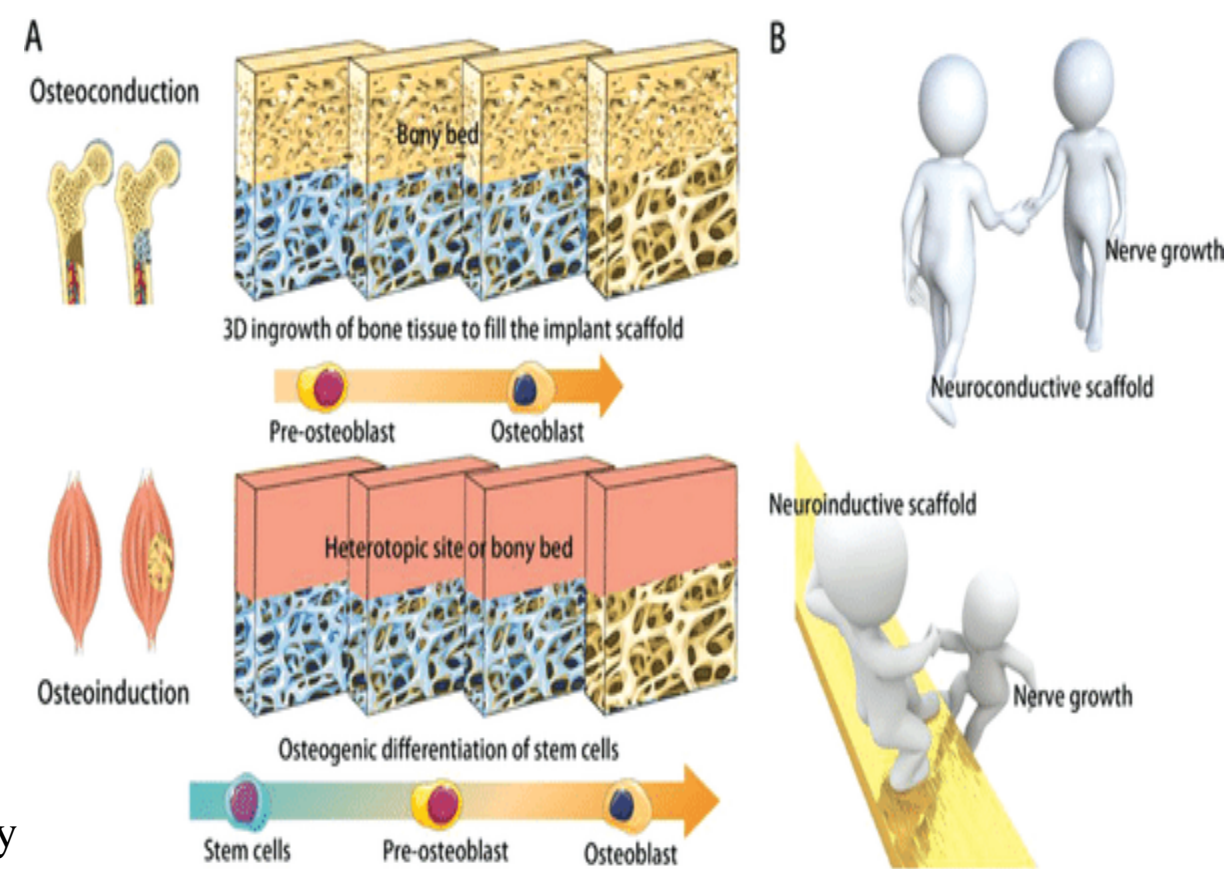
Osteoinduction: refers to **new bone formation from the differentiation of osteoprogenitor cells**, derived from **primitive mesenchymal cells**, into **secretory osteoblasts**. This differentiation is under the **influence of bone inductive proteins** or **bone morphogenic proteins (agents from bone matrix)**.

Osteoinduction implies that the pluripotential precursor cells of the host **will be stimulated** or induced to differentiate into osteoblasts by transplanted **growth factors** and **cytokines**.

Osteoconduction: is the formation of new bone from **host-derived** or **transplanted osteoprogenitor cells** along a biologic or **alloplastic framework**, such as along the fibrin clot in tooth extraction or along a hydroxyapatite block.

Osteoconductive grafts provide only a passive framework or scaffolding.

These grafts are biochemically inert in their effect upon the host.



The grafted material therefore does not have the ability to actually produce bone. This type of graft simply conducts bone-forming cells from the host bed into and around the scaffolding.

Osteogenesis: is the formation of bone from **osteoprogenitor cells**. Spontaneous osteogenesis is the formation of new bone from osteoprogenitor cells in the wound. Transplanted osteogenesis is the formation of new bone from osteoprogenitor cells placed into the wound from a distant site.

Osteogenic grafts include the advantages of osteoinductive and osteoconductive grafts in addition to the advantage of transplanting fully **differentiated osteocompetent cells** that will immediately produce new bone. **Autogenous bone is the only graft that possesses all these**

Assessment of Patient in Need for Reconstruction

Patients who have defects of the jaws can usually be treated surgically to replace the lost portion. Each patient, however, must be thoroughly evaluated because no two patients have the exact same problems. Analysis of the patient's problem must take into consideration the hard tissue defect, any soft tissue defects, and any associated problems that will affect treatment.

Hard tissue defect

Several factors concerning the actual osseous defect must be thoroughly assessed to help formulate a viable treatment plan. Adequate radiographs are necessary to evaluate the full extent of the osseous defect. The site of the defect may be just as important as the size of the defect when dealing with mandibular osseous problems. For example, if the mandibular condyle is missing, treatment is relatively more difficult. A residual portion of the ramus with the condyle still attached makes osseous reconstruction easier because the temporomandibular articulation is difficult to restore. **Soft tissue defect .**

Proper preparation of the soft tissue bed that is to receive the bone graft is just as important to the success of bone grafting as the bone graft material itself. The transplanted bone cells must survive initially by diffusion of nutrients from the surrounding soft tissues. **Revascularization of the bone graft through the development of new blood vessels from the soft tissue bed must then occur.** Thus an essential factor for the success of any bone-grafting procedure is the availability of an adequately vascularized soft tissue bed.

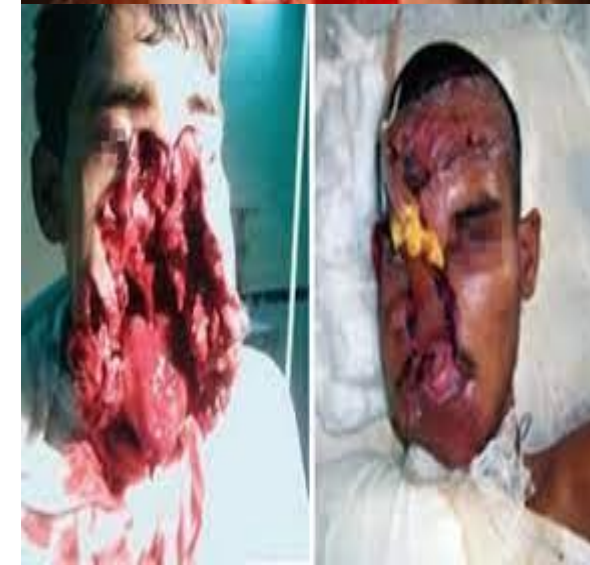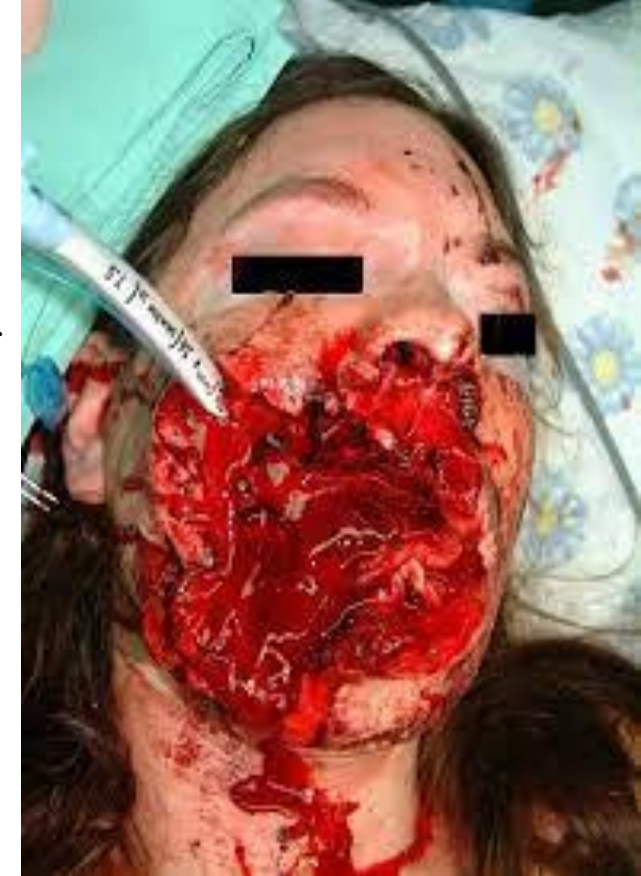Fortunately, this essential factor is usually obtainable in the lush vascular tissue of the head and neck region. However, occasionally the soft tissue bed is not as desirable as it could be, such as after radiotherapy or excessive scarring from trauma or infection. Therefore a thorough assessment of the **quantity and quality** of the surrounding soft tissues is necessary before undertaking bone graft procedures.

The reason for the osseous void often provides important information on the amount and quality of soft tissues remaining. For example, if the patient lost a large portion of the mandible from a composite resection for a malignancy, the chances are that the patient will have deficiencies in **quantity and quality** of soft tissues. During the initial surgery, many vital structures were probably removed, and denervation of the platysma muscle results in atrophy of the muscular fibers.

An intraoral examination helps the clinician determine how much oral mucosa was removed with the mandibular fragment. Frequently, the tongue or floor of the mouth appears to be sutured to the buccal mucosa, with no intervening alveolar ridge or buccal sulcus, because the gingiva is sacrificed with the osseous specimen.

If the patient received cancericidal doses of radiation to the area of the osseous defect, the clinician can assume that the patient's soft tissues have undergone extreme atrophy and scarring and will be non-pliable and fragile.

The soft tissues in this instance will provide a poor bed for a bone graft because the environment is hypovascular, hypoxic, and hypocellular. Similarly, if the patient's defect was caused by a severe infection, it is likely that an excess of scar tissue formation occurred, which will result in non-pliable, poorly vascularized tissue.



After a thorough evaluation, a decision must be made **about the adequacy of the soft tissues**. If the quantity of tissue is deficient, soft tissue flaps from the neck containing muscle and skin can be used to enhance the amount of tissue available to close over the bone graft.

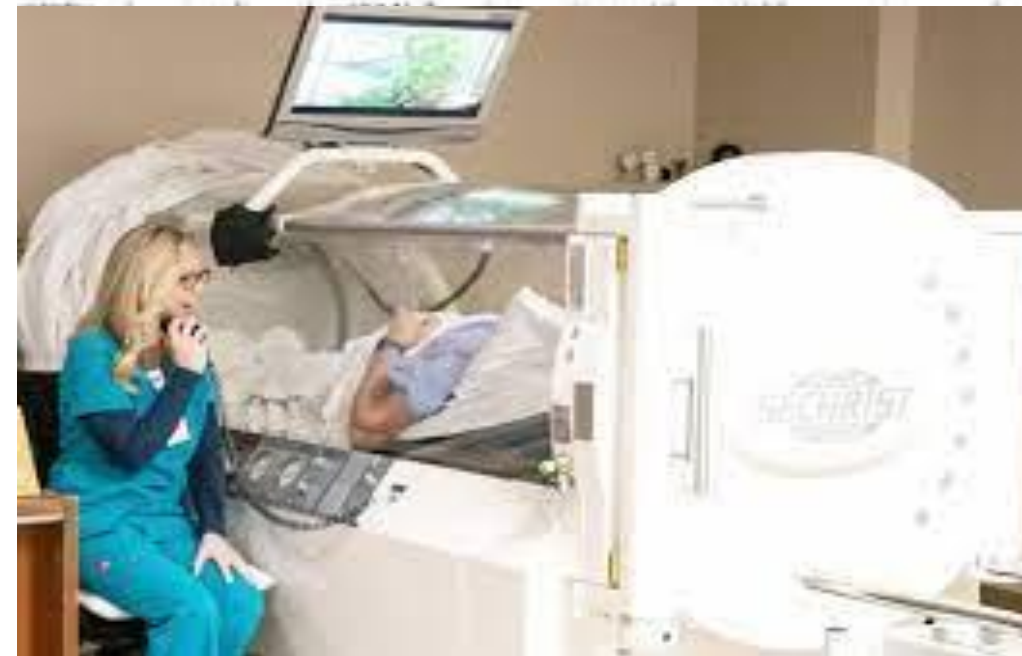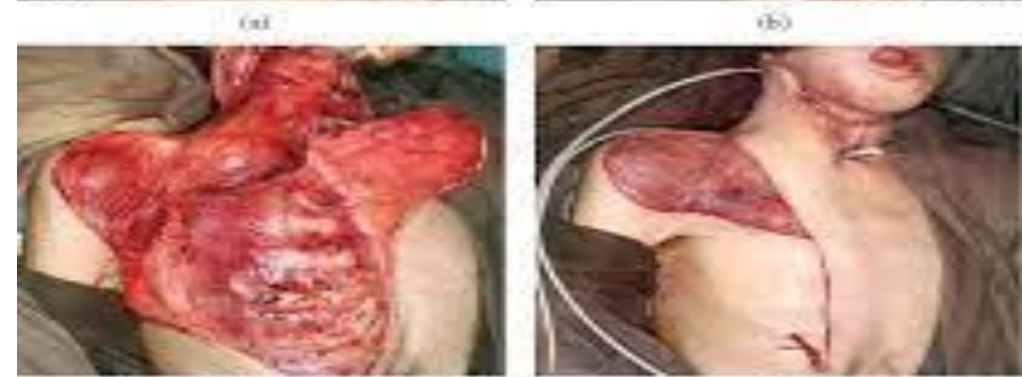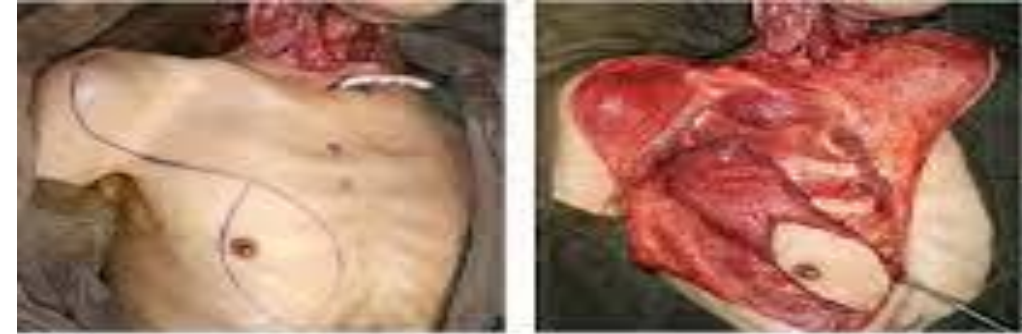If the soft tissues are deficient in quality, **one of two basic methods can be used to reconstruct a patient's defects**:

The first is to supply an autogenous bone graft with its own blood supply in the form of a free or pedicled composite graft.

The second method is to improve the quality of the soft tissues already present by the use of hyperbaric oxygen (HBO).

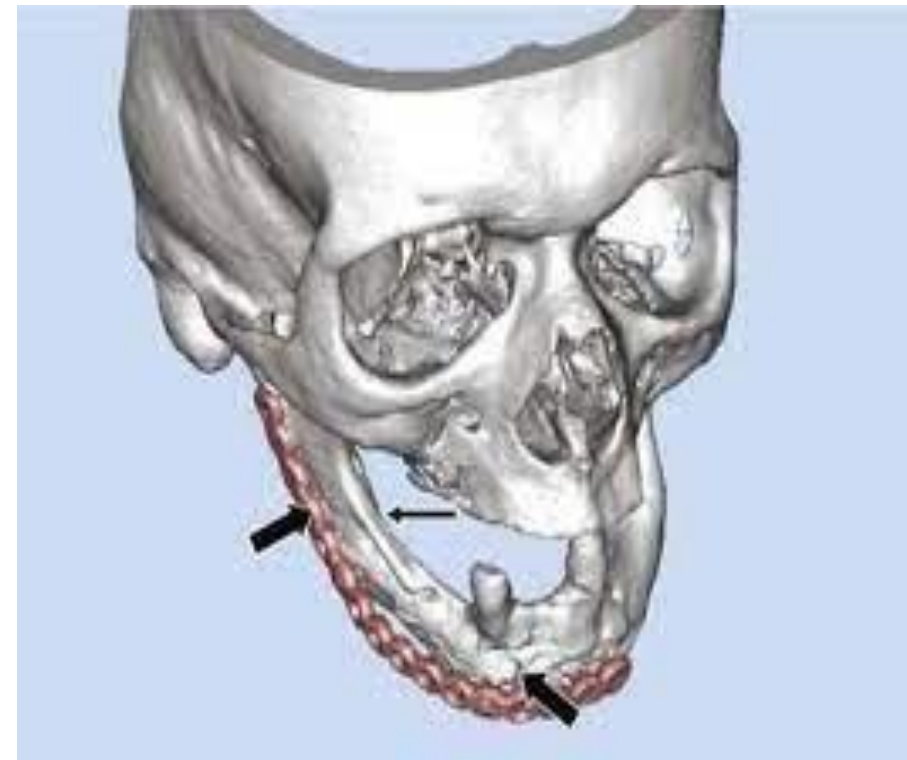
The HBO method improves tissue oxygenation by the administration of oxygen to the patient under higher-than normal atmospheric pressures. Tissue oxygenation has been shown to improve to **acceptable levels after 20 HBO treatments**. After HBO treatment, bone-grafting procedures can be performed with good success.

Another course of HBO treatment is then recommended after the bone-grafting procedure.



Associated Problems

The clinician must always remember that the cure should be less offensive to the patient than the disease process. In other words, if a reconstructive procedure will **significantly risk the individual's life** or **is associated with a very high incidence of complications that may make life worse for the patient**, it would probably be in the patient's best interest to forgo the procedure. As with any type of therapy, significant factors must be assessed, such as the patient's age, health, psychological state, and most important perhaps, the patient's desires. Thorough understanding by the patient of the risks and benefits of any treatment recommendation is imperative so that the patient can make an informed decision.

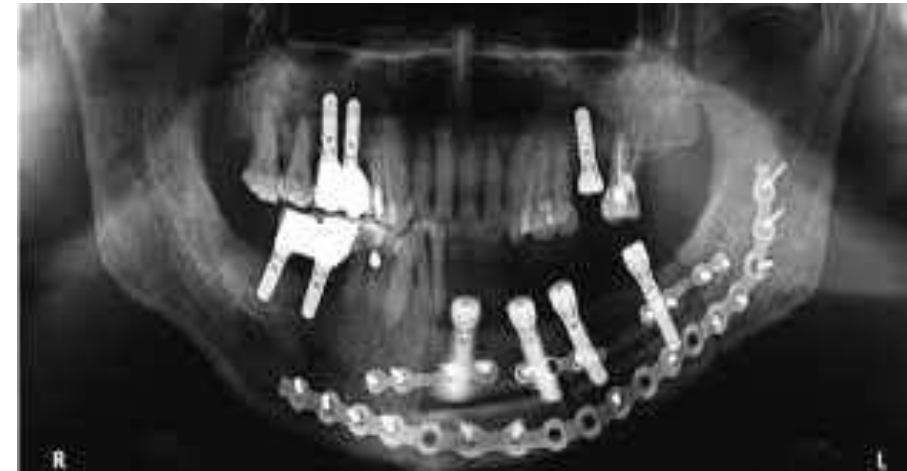


Goals of Mandibular Reconstruction

Several major goals for mandibular reconstruction that one should strive for and achieve before considering any grafting procedure a success.

□ Restoration of continuity

Because the mandible is a bone with two articulating ends acted on by muscles with opposing forces, restoration of continuity is the highest priority when reconstructing mandibular defects. Achieving this goal provides the patient with better functional movements and improved facial esthetics by realigning any deviated mandibular segments.



□ Restoration of alveolar bone height

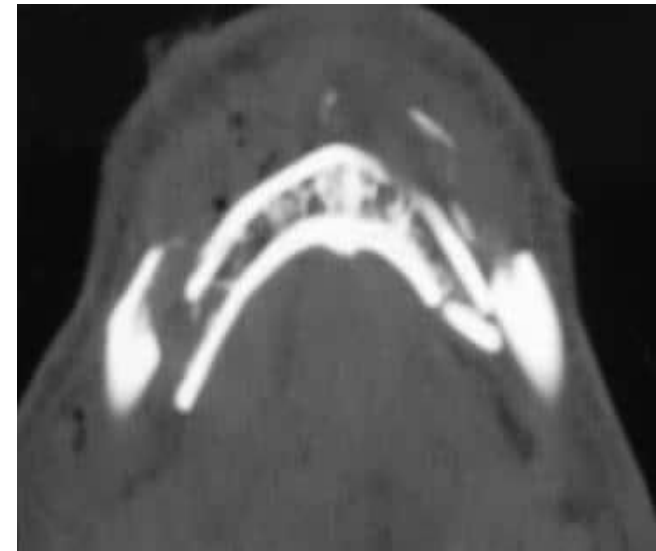
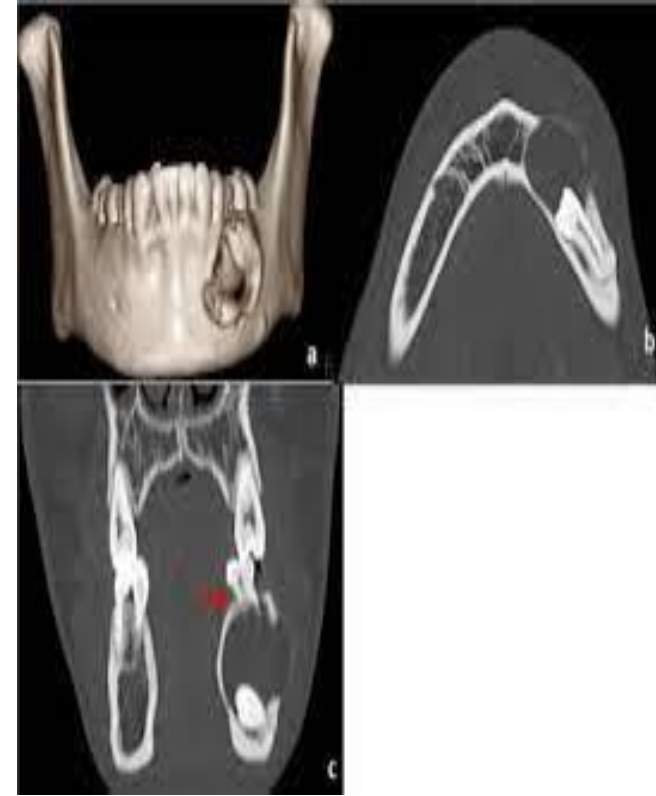The functional rehabilitation of the patient rests on the ability to masticate efficiently and comfortably. Prosthetic dental appliances are frequently necessary in patients who have lost a portion of their mandible. To facilitate prosthetic appliance usage, an adequate alveolar process must be provided during the reconstructive surgery.

□ Restoration of osseous bulk

Any bone-grafting procedure must provide enough osseous tissue to withstand normal function. If too thin an osseous strut is provided, fracture of the grafted area may occur.

Diagnosics

Radiographic imaging is of utmost importance for planning a surgical procedure, along with investigations of medical history and physical examination of the patient. Panorama radiography is a fundamental basis in oral and maxillofacial imaging to picture the mandible and is supplemented by three dimensional imaging. Computed tomography (CT) represents the standard for skeletal imaging, whereas digital volume tomography (DVT) (also known as CBCT) only emerged in the past years and is predominantly used to depict bone with shortcomings in soft tissue imaging.



CT scans provide the option to create virtual three-dimensional models of the bony surface in combination with multiplanar projections. They facilitate surgical decisions and help anticipate possible difficulties that may occur during surgery. Virtual surgical planning is a relatively new technology that gained importance in complex osseous craniofacial reconstruction. It enables a higher precision, improves operative efficiency, and ensures an enhanced surgical outcome.

Computer-aided design (CAD) and computer-aided manufacturing (CAM) offer integration possibilities for a variety of tools to enhance surgical planning and execution. Virtual three-dimensional models or stereolithographic models can support the creation of cutting guides, individualized plates, and drilling jigs. It has been shown that CAD/CAM prefabricated adjuncts improve accuracy in terms of bone-to-bone contact, improved facial contour, and fewer complications.

These models are the basis for further surgical guides or reconstruction plates.

Defect Types and Localizations :

Depending on the defect localization, there are different esthetic and functional deficits that require special planning and treatment procedures. There have been a number of classifications and variations to systemize defects of the mandible, mainly to simplify the treatment planning in surgery. As it turns out though, the establishment of an ideal system that covers all relevant aspects in terms of inclusion of soft and hard tissue defects, benign and malignant tumors and surgical planning is difficult.

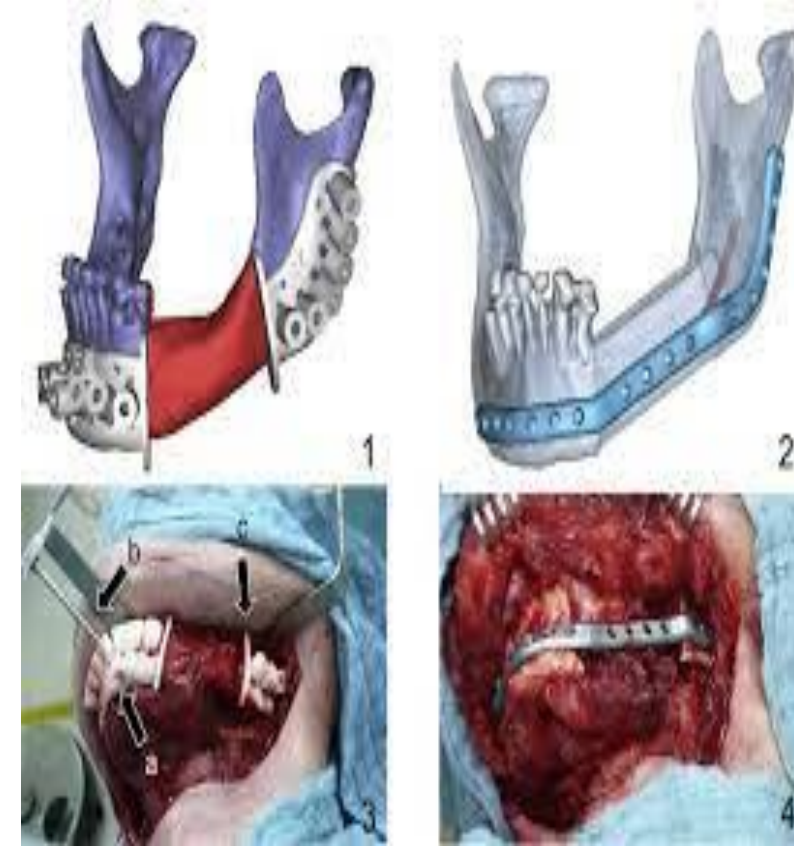
Jewer and colleagues introduced the HCL system, which is often referred to in literature. They considered three main defects (H, lateral segment from midline including the condyle; C, anterior segment including the canines; L, lateral segment from midline to the ascending branch excluding the condyle) resulting in eight defect classes when combined. This approach, for example, aims to figure all possible units of defects and encompasses reconstructive aspects.

Mandibular Reconstruction

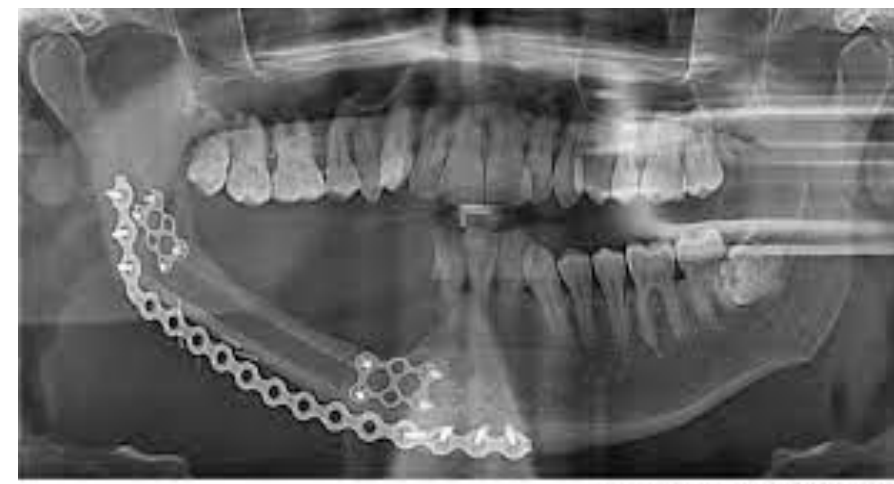The maxillofacial surgeon faces many challenges in mandibular reconstruction in terms of contour and functional needs. In the past, autologous nonvascularized bone transplants in combination with internal or external osteosynthesis were the first steps in free tissue transfer for bony recovery. Extensive resorption, lack of engraftment of the transferred bone, and instability of the osteosynthesis material prevented resounding success. Other more complex approaches consisted of local pediculated osseomyocutaneous flaps. The major pectoralis muscle flap in combination with a rib, the sternocleidomastoid flap with part of the clavicle, or the trapezius muscle flap with a portion of the scapula has been introduced for mandibular reconstruction. Despite the better prognosis of the transferred bone, these techniques were limited to only a few indications due to their high donor site morbidity and the poor outcome in terms of function and esthetics.

The progress in microvascular surgery over the past 30 years led to a new era in reconstructive head and neck surgery with a variety of options for the recovery of the mandible.

The repertoire comprises grafts for different three-dimensional defect sizes that enable the surgeon to react to donor site limitations of the patient. Today, there are various reconstructive options in the therapeutic range for mandibular recovery.



The pioneering work in the early 1970s with revascularized rib for restoration of the mandible paved the way for modern microsurgical approaches. It has been shown that single bone defects or composite tissue defects of the lower face can be reconstructed in a reliable and relatively safe manner. Even the engraftment in an irradiated setting proved to be possible with vascularized free bone grafts. **Iliac crest, scapula, fibula, and other bones emerged as the most common and promising donor sites.**



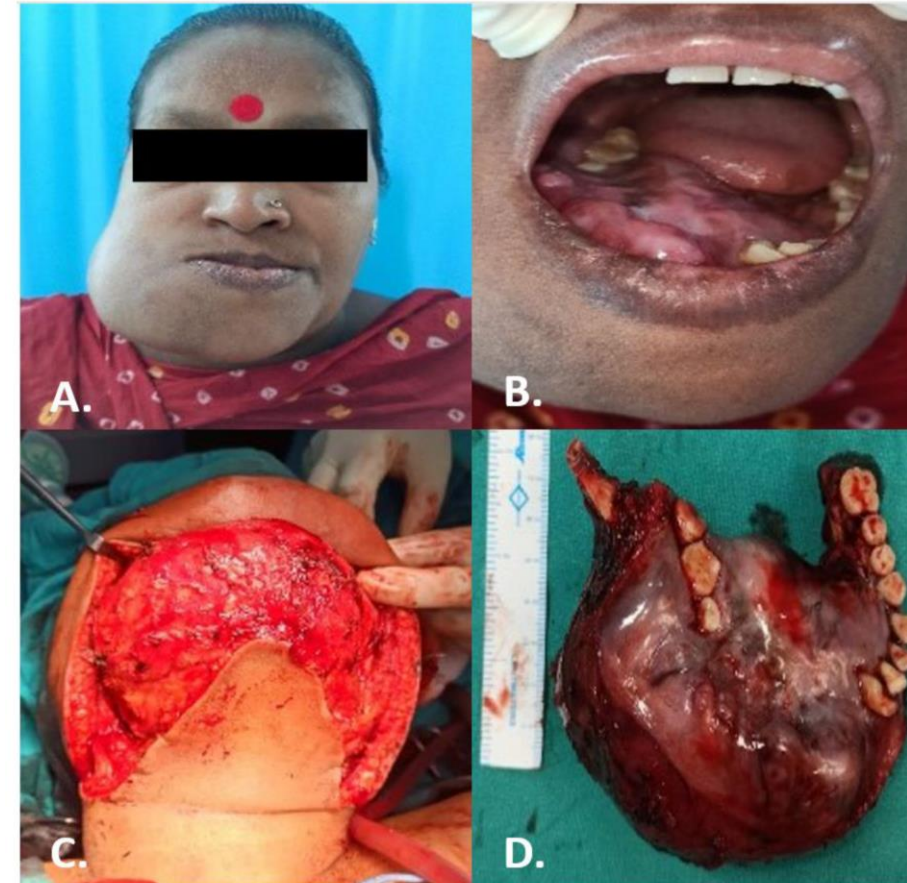Today, they are the **gold standard for mandibular reconstruction**. The reconstruction with vascularized osseous free flaps has become a safe and consistent procedure with a success rate of more than 90%.

The common feature of all approaches is that the free vascularized bone graft is initially protected by titanium reconstruction plates.

The indications of microvascular free flap are limited to salvage surgery, lacking other therapeutic options.

Surgical Principles of Maxillofacial Bone Grafting Procedures

Several important principles should be followed during any grafting procedure. They must be strictly adhered to if a successful outcome is desired. The following are a few that pertain to reconstructing mandibular defects:



1- Control of residual mandibular segments:

When a continuity defect is present, the muscles of mastication attached to the residual mandibular fragments will distract the fragments in different directions unless efforts are made to stabilize the remaining mandible in its normal position at the time of partial resection. **Maintaining relationships of the remaining mandible fragments after resection of portions of the mandible is a key principle of mandibular reconstruction.** This is important for occlusal and temporomandibular joint positioning. When the residual fragments are left to drift, significant facial distortions can occur from deviation of the residual mandibular fragments. Metal bone plates inserted at the time of resection are useful for controlling the position of the mandibular fragments. These plates are of sufficient strength to obviate the need for intermaxillary fixation, permitting active use of the mandible in the immediate postoperative period. In older individuals or those with significant medical compromise, this may be the final form of reconstruction. **Use of bone plates provides soft tissue support to maintain facial symmetry.**

When the mandibular symphysis has been removed, the tongue can be sutured to the plate, maintaining its forward position to prevent airway obstruction. The bone plate can be left in place when the mandible is secondarily reconstructed with bone grafts, permitting mobility of the mandible during the healing phase of the bone graft. When the position of the residual mandibular fragments have not been maintained during the resection, realignment is more difficult during the reconstructive surgery. Over time the muscles of mastication become atrophic, fibrotic, and nonpliable, which makes realignment of the fragments extremely difficult.

During the reconstructive surgery, it may be necessary to strip several muscles off the mandibular fragments to release the bone from their adverse pull. A coronoidectomy is usually performed to remove the superior pull of the temporalis muscle. Before inserting a bone graft, the clinician must be sure to reach the desired position of the remaining mandibular fragments because what is achieved at surgery is what the patient must live with in the future.

If the mandibular condyle has been resected or is unusable, reconstruction of the condyle with a costochondral junction of a rib or alloplastic condyle is necessary to maintain the forward position of the reconstructed mandible.

2- A good soft tissue bed for the bone graft:

All bone grafts must be covered on all sides by soft tissues to avoid contamination of the bone graft and to provide the vascularity necessary for revascularization of the graft. Areas of dense scar should be excised until healthy tissue is encountered. Incisions should be designed so that when the wound is closed, the incision will not be over the graft, which means that the initial incision may be very low in the neck. A multilayered soft tissue closure is performed to reduce any space that might allow collection of blood or serum and to provide a watertight closure.

3- Immobilization of the graft:

Immobilization of bone is necessary for osseous healing to progress, which is why orthopedic surgeons apply a cast to a fractured extremity. In dealing with mandibular defects, the graft must be secured to remaining mandibular fragments, and these fragments must be rigidly immobilized to ensure that no movement exists between them. This immobilization is most often provided by the use of intermaxillary fixation, in which the mandible is secured to the maxilla. However, several other methods are possible, such as using a bone plate between the residual bone fragments. Immobilization for 8 to 12 weeks is usually necessary for adequate healing between the graft and the residual mandibular fragments.

4- Aseptic environment:

Even when transplanting autogenous osseous tissue, the bone graft is basically avascular, this means that the graft has no way of fighting any amount of infection. Therefore a certain percentage of bone grafts become infected and must be removed. Several measures can be taken to improve the success of bone-grafting procedures. The first is to use an extraoral incision where possible. The skin is much easier to cleanse and disinfect than is the oral cavity. Bone grafts inserted through the mouth are exposed to the oral flora during the grafting procedure. Furthermore, the intraoral incision may dehiscence and again expose the bone graft to the oral flora.

Bone grafts placed through a skin incision are more successful than those inserted transorally. However, it is important that during the extraoral dissection the oral cavity is not inadvertently entered. Ideally, dissection to the level of the oral mucosa without perforation is preferred.

5- Systemic antibiotics:

The prophylactic use of antibiotics may be indicated when transplanting osseous tissue. Prophylaxis may be beneficial in helping reduce the incidence of infection.

Maxillary Reconstruction

Maxillary and midface reconstruction is more challenging than most oromandibular defects for several reasons:

- Complex geometry
- Distance of target vessels for revascularization
- Impaired access and visibility without transfacial incisions
- Exposure to the sinus, nasal, and oral cavities

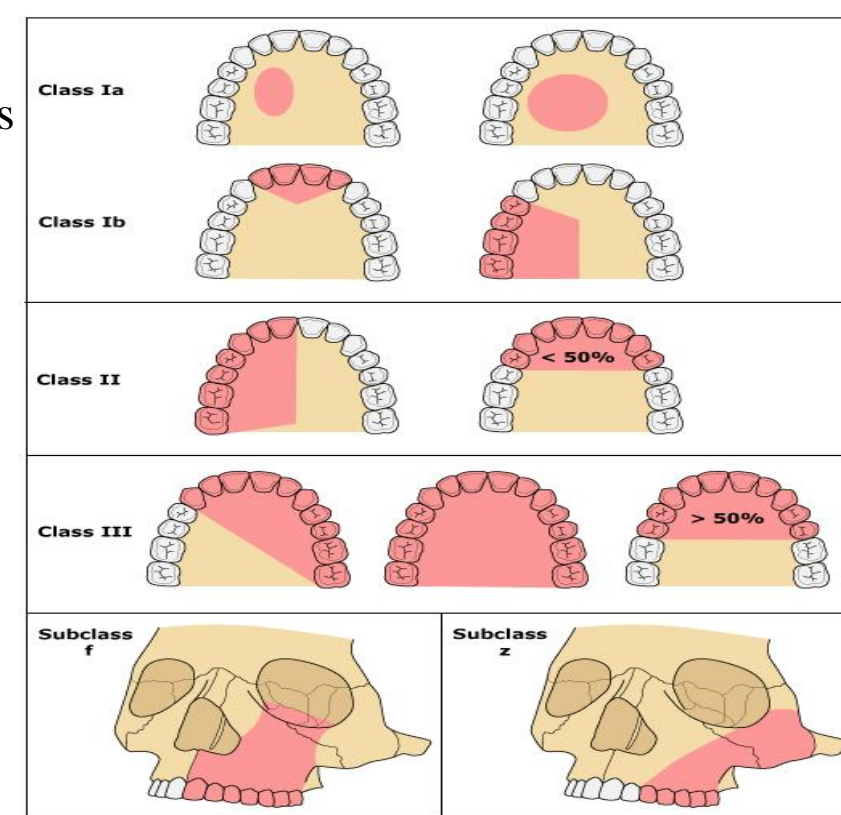
As a result, maxillary reconstructions have typically had lower success rates than comparable mandibular defects. That said, maxillary defects lend themselves to myriad reconstructive options including prosthetics.

Defect Classification

Two classifications have been selected because of their simplicity and their comprehensive applicability. Both systems describe the vertical and horizontal components of the defects to provide a three-dimensional description of the defect.

O

Key classification of Maxillary Defects



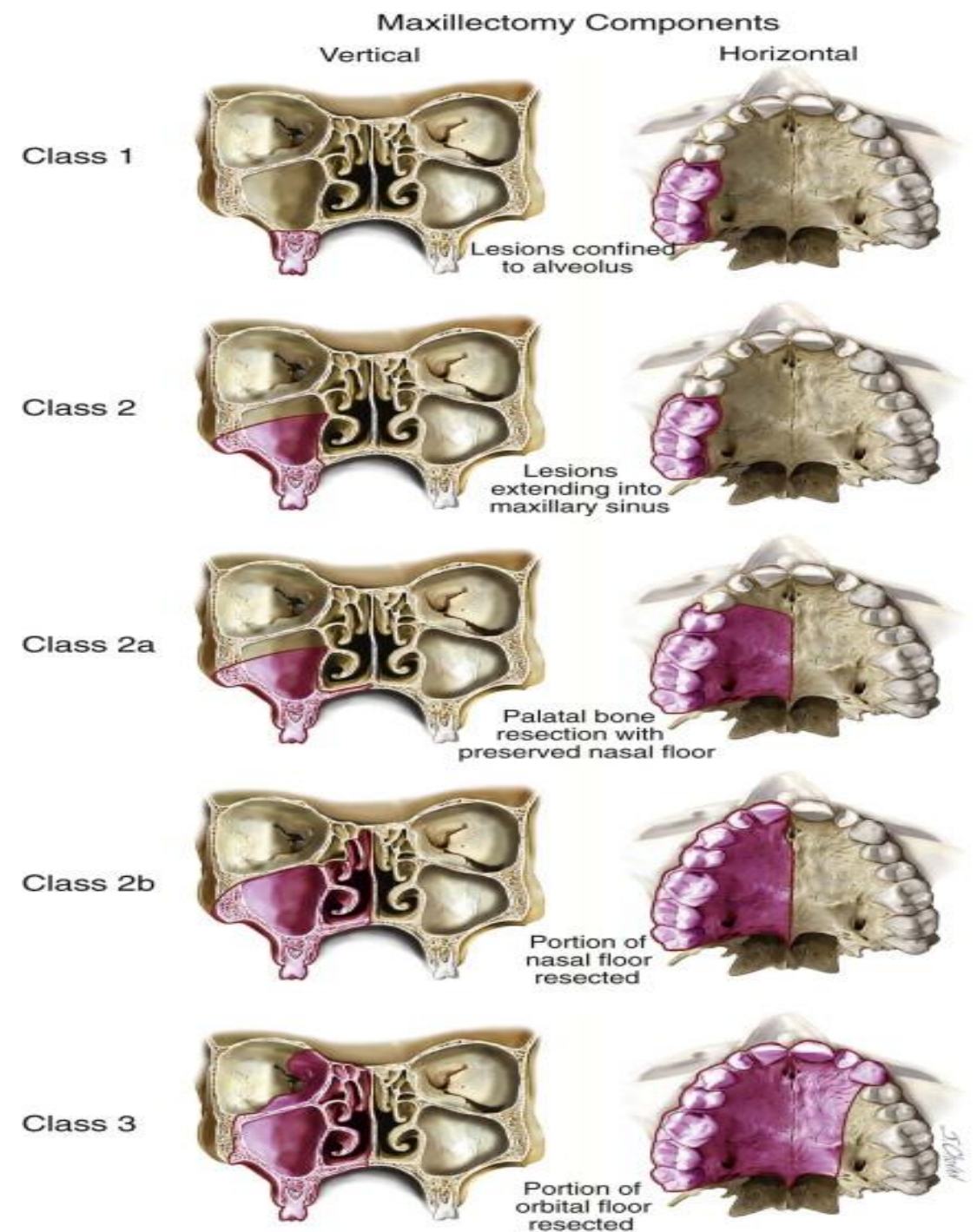
Defect Class	Criteria
Ia	Limited defect in the central portion of the palate that does not involve the alveolus
Ib	Defect in the palate that involves the alveolus but is located posterior to the canine or is limited to the premaxilla with preservation of the canine teeth bilaterally
II	Hemi-palatal defect that does not cross the midline in a "conventional" longitudinal resection and does not extend posterior to the midpoint of the palate for a defect that is created in the horizontal orientation, thus preserving at least half of the palatal surface
III	A subtotal or total palatotomy that involves more than one half of the palatal surface
f	Indicates a defect in the floor of the orbit
z	Indicates a defect in the body of the zygoma

Brown classification :

This classification system was introduced by Brown and Shaw in 2010.

Their system subdivides the vertical, described numerically, and horizontal components, described alphabetically, of maxillectomy defects.

Defects are graded vertically from I to IV based on their extension from the maxillary alveolus toward the cranial base. Class I defects are limited to alveolus and palatal bone only. By definition, these defects do not involve the maxillary antrum. Also known as low maxillectomies, class II defects include alveolus and antral walls, but do not involve the orbital floor. Class III defects, or high maxillectomies, extend further superiorly to include the orbital floor; however, by definition the globe is not involved in the resection. Also known as radical maxillectomies, class IV defects are essentially the same as class III defects in terms of bony involvement, but orbital exenteration is included in the resection. Class V and VI were later added in the modified system to address isolated orbitomaxillary and nasomaxillary defects respectively. Unlike the traditional class I to IV defects, these special categories do not involve the lower maxilla and alveolus.



Within the modified Brown classification, horizontal extent is graded separately as either a, b, c, or d. Isolated defects of the palate not including the alveolus are termed a. Defects involving 50% or less of the transverse width of the maxilla are termed b. Horizontal anterior defects of the maxilla are termed c. Large horizontal defects involving greater than 50% of the transverse width are termed d.

Maxillary defect reconstruction :

Brown class 1 defects can be treated with local flaps, or with an obturator if there is an oro-antral or oronasal communication.

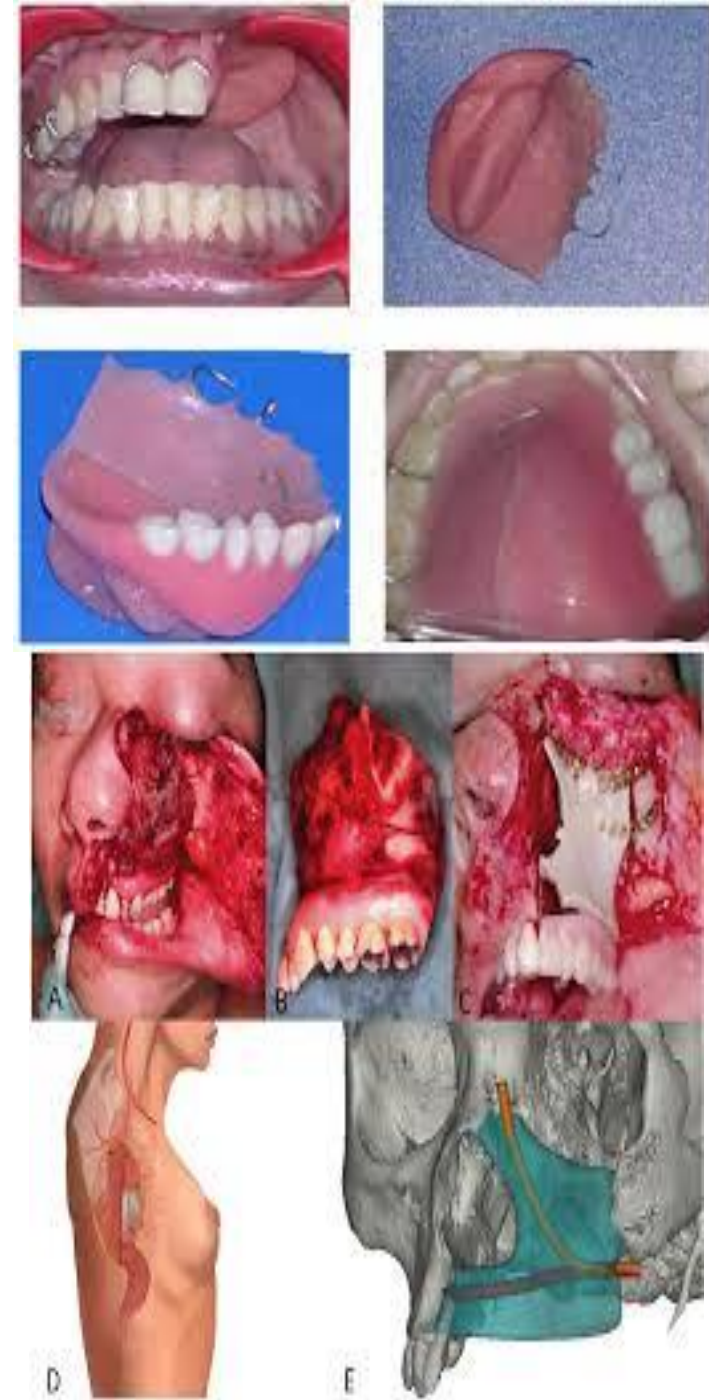Similarly, class 2a defects can be obturated, or reconstructed with local and pedicle flaps, or a combination of both. As the horizontal extent increases, such as in classes 2b and 2c, prosthetic rehabilitation with an obturator becomes more difficult and implant support may become necessary to improve stability.

Consequently, a composite flap may be used to assist with soft tissue closure and provide bone for implant placement.

Class 3 defects, involving midline and cross-midline structures, are usually not treated with obturators, because the weight and size of a device presents challenges in achieving a functional and stable prosthesis.

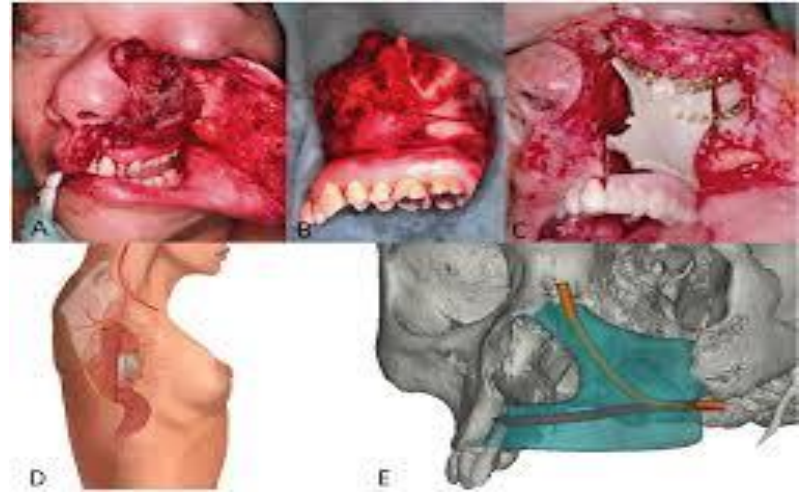
For Classes 3b and 3c defects, a composite vascularized flap capable of addressing both maxillary and orbital defects is the recommended treatment.

Class 4 defects are almost never amenable to obturator rehabilitation without free flap reconstruction, as they involve the entire orbit and sometimes the cranial base. A composite free tissue transfer that provides not only bone, but also a generous amount of soft tissue for closure of fistulas, obturation of the orbit, and sealing of cranial communications is needed.



Goals of maxillary reconstructive surgery

- Preservation of normal speech, swallowing, and velopharyngeal function
- Close oral-antral and/or oral-nasal fistulae
- Maintain nasal patency
- Obliterate postoperative dead space
- Expedite wound healing and transition to adjuvant therapy
- Maximize mouth opening and masticatory function
- Maintain functional lip competence
- Provide vertical support to the globe and associated facial soft tissues
- Create a stable preprosthetic framework for implant reconstruction and/or obturator fabrication



Pediatric patients

Wherever possible, pediatric patients should be obturated while they are growing. If a bone **flap is placed, there is a risk that the flap will not grow**. Lack of growth of the flap will then have a reciprocal effect on the **remaining maxilla** and **result in a secondary deformity that can be prevented with a temporary prosthetic option**.

Second, if the flap is not restored with teeth, there will be no antagonist for the opposing teeth. These will then super-erupt, leading to a secondary deformity in the opposite jaw that can only be corrected with an osteotomy.

A prosthetic solution allows a child to have a functional reconstruction that provides a dentition to prevent a deformity in the opposite jaw and permits normal growth and development in the remaining maxilla. It is also the most efficient process to allow a child to resume their normal academic, athletic, and social activities that are so important in the younger years of life. Most children adapt very quickly to a prosthetic option.

COMPUTER-ASSISTED SURGICAL PLANNING

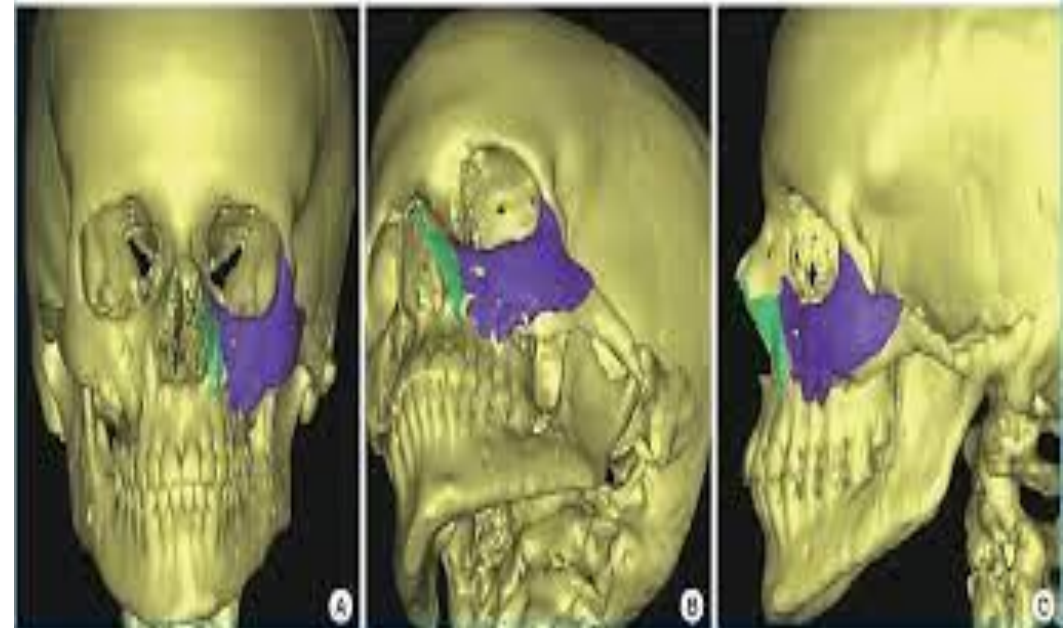
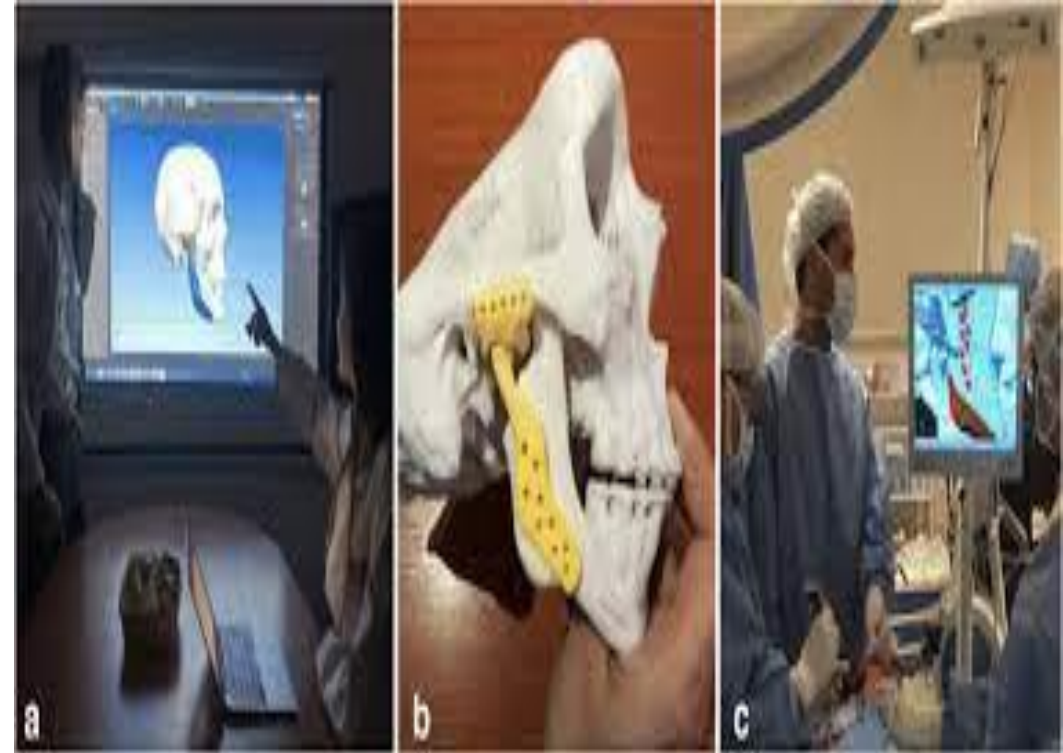If a bony reconstruction of the maxilla is to be accomplished, it should be correct in both position and form. The complex three-dimensional nature of the maxilla and associated parts makes virtual planning particularly valuable. Virtual planning may take many forms in maxillary reconstruction according to the needs and preferences of the surgeon. At a minimum, it can help ensure appropriate positioning of the bone flap over the opposite arch with adequate inter-arch space for a dental rehabilitation.

Unlike most oromandibular reconstructions, where the defect is contiguous with the neck and easily visualized, maxillary defects are often approached with more limited incisions, and the vessels are transferred to the neck through a tunnel in the cheek. This makes shaping a flap difficult to do in situ.

A stereolithographic model of the patient's skull with the proposed resection completed is an invaluable tool for flap shaping ex vivo.

Fixation may also be shaped and applied to the flap using the model, greatly facilitating inset and saving significant amounts of operating room time.

Once shaped and fixation applied, it can then be inserted into the prepared defect with the only focus on appropriate position.



Flaps for Maxillofacial Reconstruction

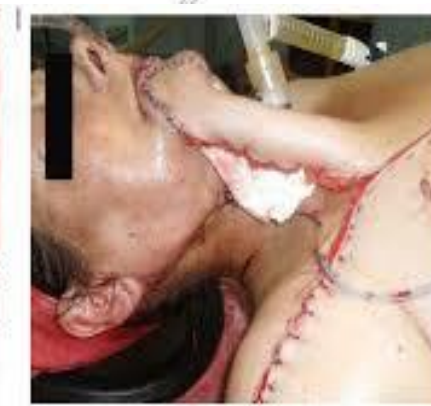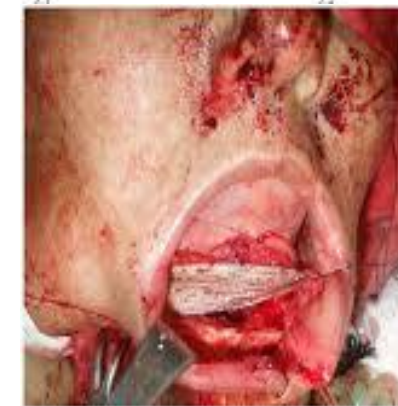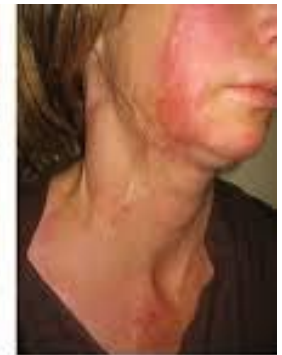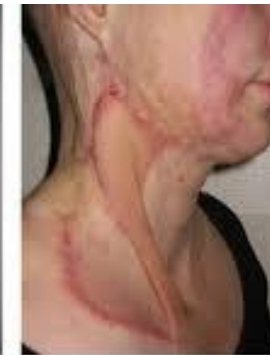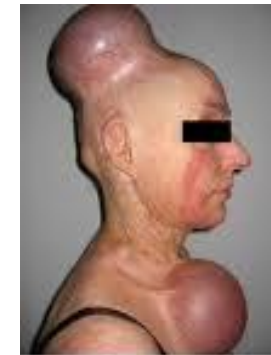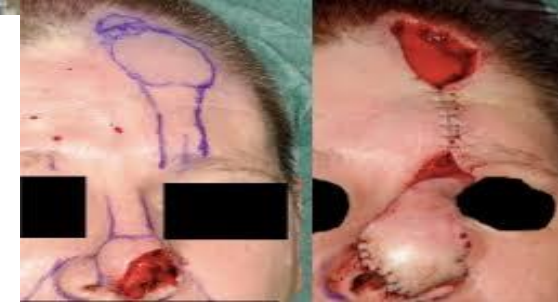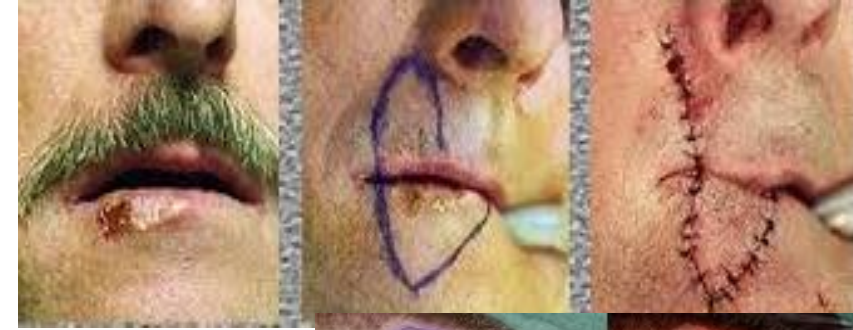The term flap originated in the **16th century** from the **Dutch word “flappe,”** meaning something that **hung broad and loose, fastened only by one side.** The history of flap **dates as far back as 600 BC,** when Sushruta Samita described **nasal reconstruction using a cheek flap.**

A flap in technical terms is a tissue that is transferred from one side (donor site) to another (recipient site) while **maintaining its own blood supply.**

Depending on the position of the **donor and recipient sites,** flaps can be broadly classified as **local** or **distant** (regional) flaps

Local flaps are those that are derived from the **immediate area of resection** **common examples** of these **include buccal pad of fat flap, nasolabial flap,** and **facial artery musculomucosal (FAMM) flap.** These types of flap are advanced, transposed, or rotated into position and a supplied by either an axial pattern or by a random pattern. Axial flaps receive their blood supply from a single nutrient vessel whereas random pattern flaps receive capillary blood supply in a random pattern from all direction and not from a single nutrient vessel. The Rehrmann buccal advancement flap is good example of a random flap.

In distant or regional flaps the donor site is distant from the recipient site. These flaps were used to be the workhorse of reconstruction of the oral cavity in the past, but they are now losing their shine due to introduction of better options.



The flap is similar to but different from a graft, which does not have an intact blood supply and therefore **relies on growth of new blood vessels**. This is done to fill a defect such as a wound resulting from injury or surgery when the remaining tissue is unable to **support a graft**, or to **rebuild more complex anatomic structures such as the jaw**.

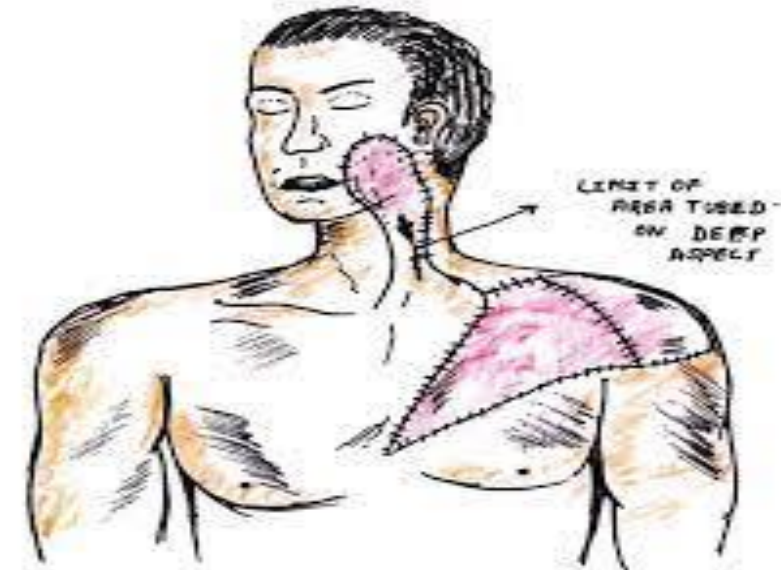
Classification of flaps may be defined by the configuration, tissue layers, blood supply, region, and method of transfer. **Tissue configuration describes the geometric shape of the flap**. These flaps include rhomboid, bilobed, z-plasty, v-y, rotation, and others. Flaps can also be classified by their tissue content. **These flaps include:** cutaneous (skin and subcutaneous tissue), **myocutaneous (composite of skin, muscle, and blood supply)**, and fasciocutaneous (deep muscle fascia, skin, regional artery perforators).

Arterial supply can be used to **classify a cutaneous flap as a random pattern, axial pattern, or pedicle flap**.

Axial Pattern Flap – A single flap which has an anatomically recognized arterio-venous system running along its long axis. Such a flap, because of the presence of its axial arterio-venous system, is not subject to many of the restrictions which apply to flaps in general

Differences between flap and graft:

graft	flap
Limited to transplantation of skin	Can carry other tissues
Depends on recipient site on nutrition	Has its own blood supply
Cosmetic – may discolor or contract	Better color take and less likely to contract
Less adaptable to weight bearing	Most adaptable to weight bearing
Less able to survive on a bed with questionable nutrition	Can be used on a bed with questionable nutrition
Requires pressure dressing	Does not require pressure dressing
Cannot bridge defects	Can bridge defects



Random Pattern Flap - has no named blood supply, rather, it uses the dermal (mucosal) and subdermal (submucosal) plexus as its blood supply.

Pedicled flaps- remain attached to the donor site via a pedicle that contains the blood supply (in contrast to a free flap).

Classification can also be based on the **relative location of the donor site**.

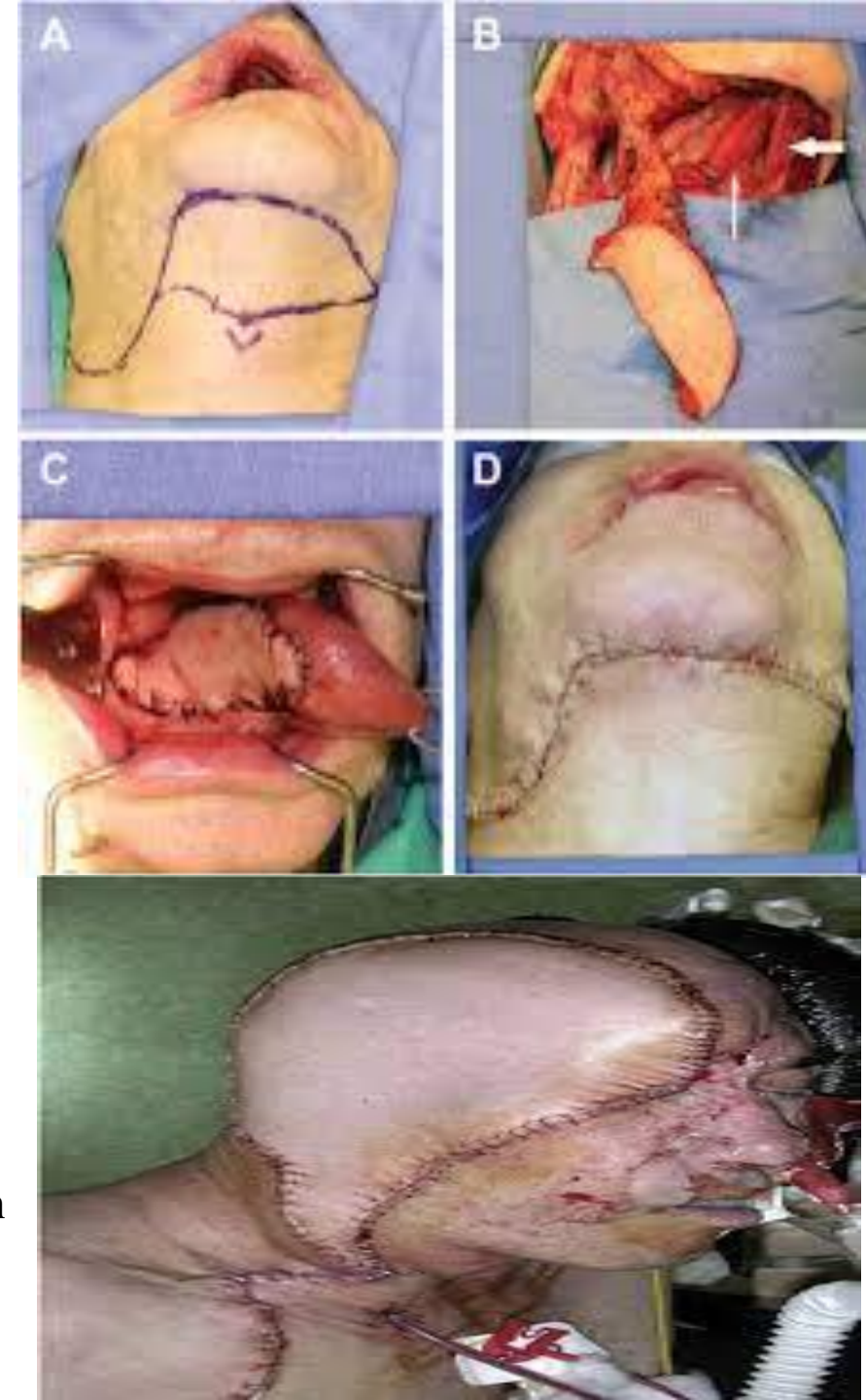
Local flaps are considered adjacent to the primary defect.

Regional flap donor sites are located on different areas of the same body part. If different body parts are used as the donor site, the flap is termed a distant flap.

Description of the flap movement is the most common method of classifying reconstructive techniques.

Advancement flaps, rotation flaps, transposition flaps, interposition flaps, and interpolated flaps are common techniques.

Advancement flaps use mobilized tissue in a direction toward the primary defect. Rotation flaps pivot mobilized tissue around a point toward the primary defect. Transposition flaps are mobilized tissues that traverse adjacent tissue by rotation and/or advancement in an effort to close the primary defect. When the adjacent tissue is also mobilized to close a defect by secondary movement, the flap is classified as an interposition flap. Interpolated flaps are mobilized tissues that traverse over or beneath an otherwise non-compromised skin bridge in the form of a pedicle to close the primary defect.



The pedicle consists of skin (possibly subcutaneous fat and muscle) and/or an individual artery and vein used, with adjacent tissue, to maintain vascularity of the flap. At least one additional procedure is required to divide a pedicle.

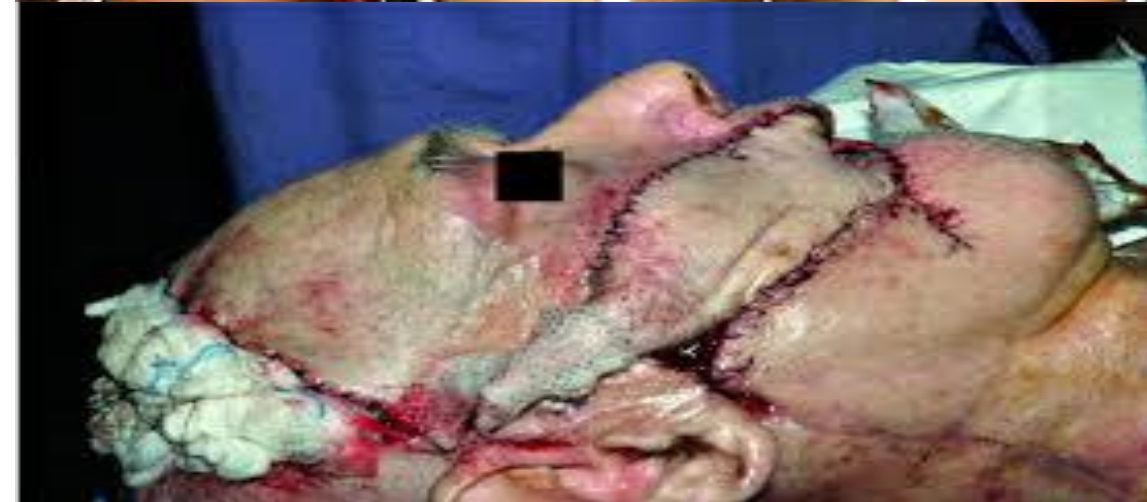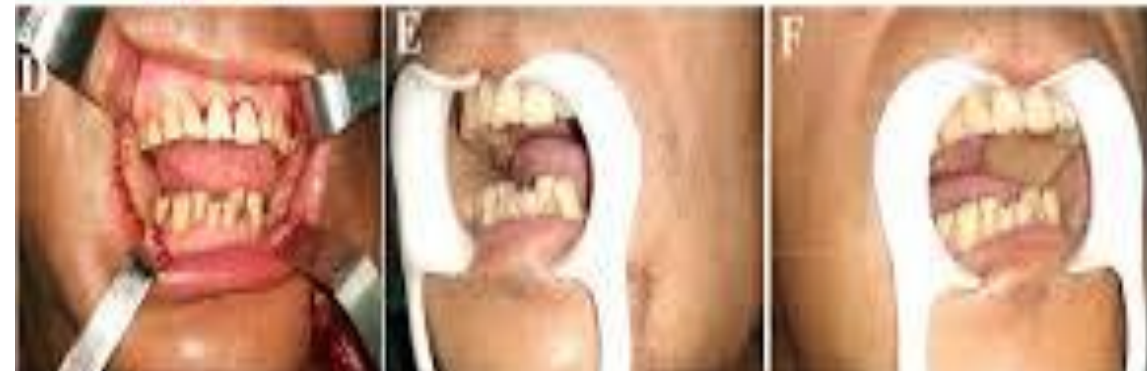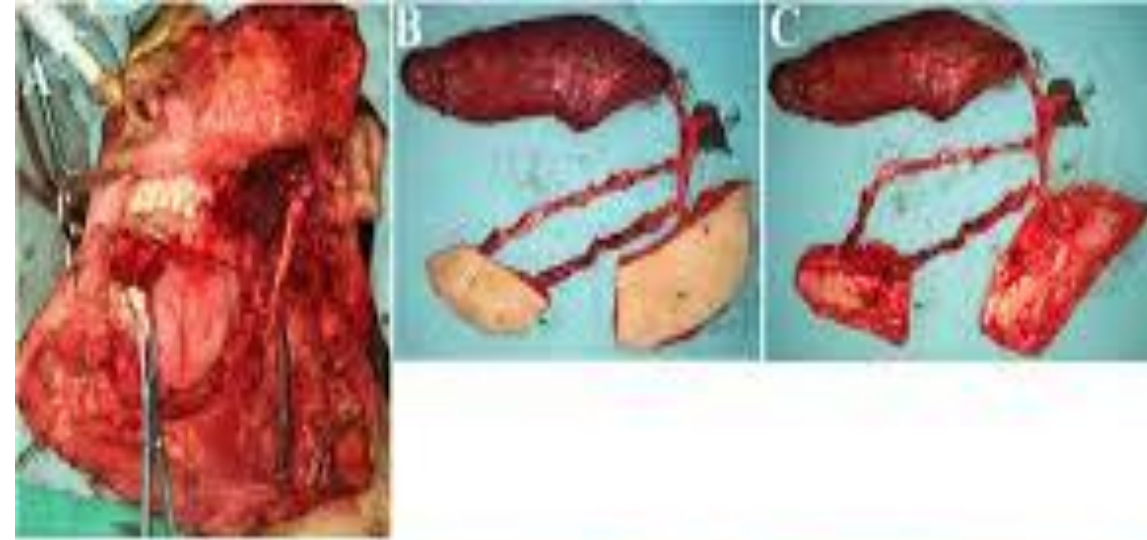
Microvascular free tissue transfer utilizes tissue transferred from a different part of the body and, unlike local or regional flaps, distant or microvascular free flaps require the detachment of the feeding vessels and transfer of the flap to the recipient site and anastomosing the vessels to a recipient artery and vein or veins.

The advantage of this method of reconstruction is that the surgeon is no longer limited to the amount of tissue in the vicinity of the defect nor the arc of rotation of the flap. It enables the use of small to large or simple to complex tissue transfer.

The obvious disadvantage is that when the skin in the head and neck needs to be reconstructed, **the color match and texture will be significantly different.**

Examples of Flaps used in Maxillo-Mandibular Reconstruction

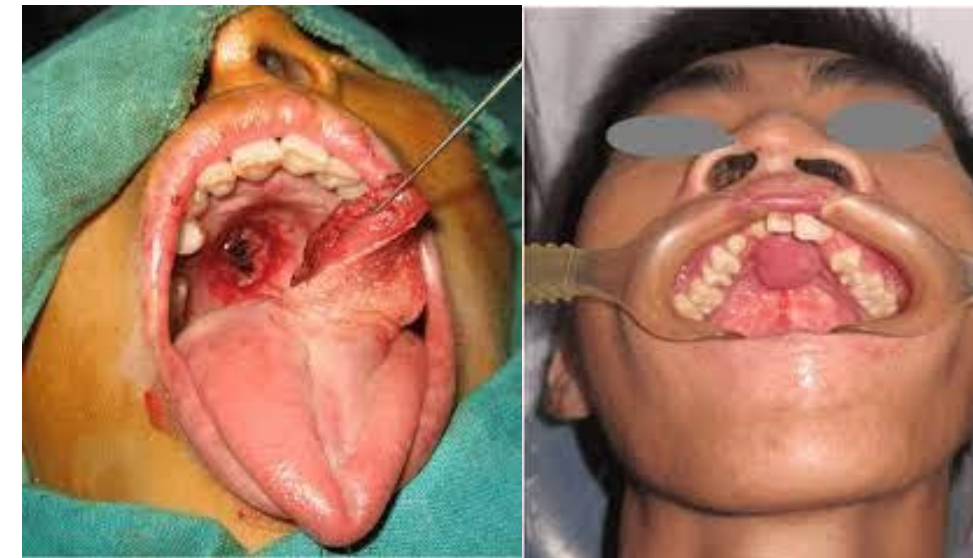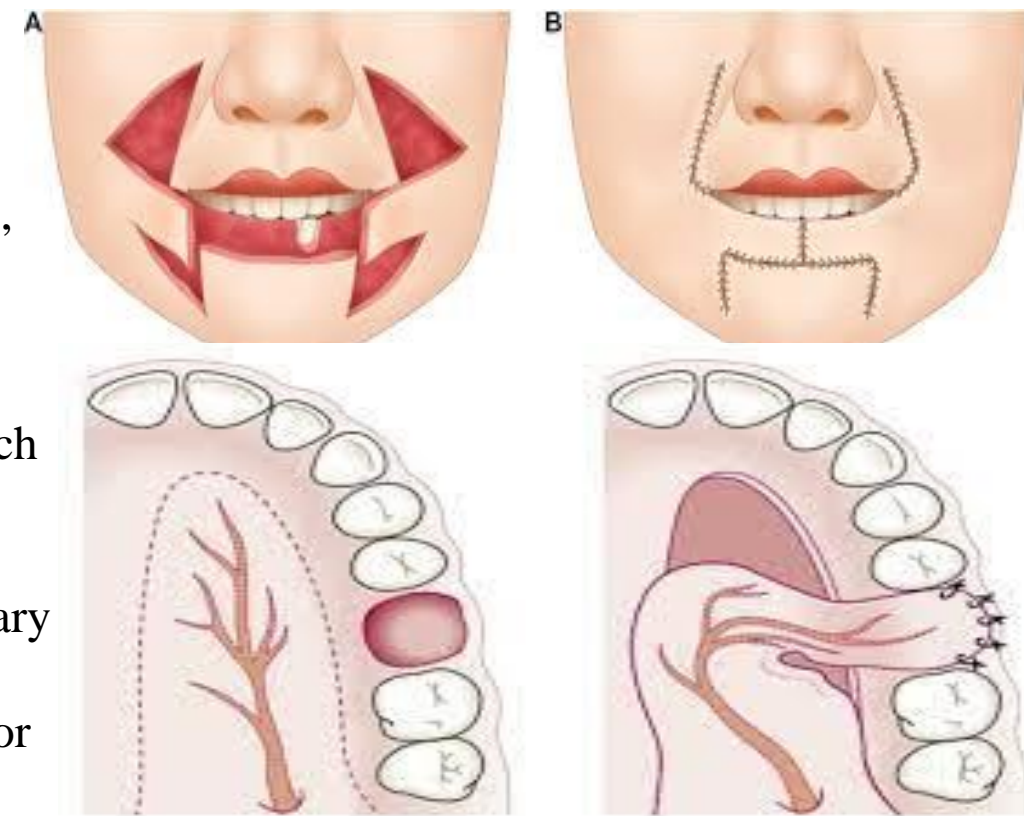
□ **Palatal Flap:** represents the most commonly used local reconstruction in oral and maxillofacial surgery for the closure of oro-antral fistulas following dental extractions. Palatal reconstructive flaps can be unilateral or bilateral, which are pedicled flaps based on the palatal artery and vein.



The entire palatal mucosa can be raised and rotated as a flap or a finger flap alone can be used. The donor area is left for secondary granulation and is mucosalised in three to five weeks yielding a smooth surface. The area should generally be protected during healing and can be painful to the patient. In total, up to 16 cm² can be harvested.

□ **Tongue Flap:** Tongue flaps have been used in the reconstruction of local defects of the floor of the mouth as well as in palatal defects since introduced by Eiselsberg and Lexer 1909. The flap is easy to raise and can reach 4 to 5 cm depending on the donor site used; dorsal flaps are used for palatal defects and lateral or ventral flaps are suitable for the mandible or the floor of the mouth. Tongue flap can be anteriorly based or posteriorly based. The primary drawback stems from the donor site, the tongue specifically. The tongue is sensitive and all procedures cause scarring, resulting in potential morbidities for the patient that involves speech and feeding. Leaving the tip of the tongue unharmed is of primary importance.

□ **Buccal Fat Pad Flap:** Ideally suited for small retromolar and posterior maxillary defects, this axial pattern flap enjoys a robust blood supply with contributions from the buccal and deep temporal branches of the maxillary artery, the transverse facial branch of the superficial temporal artery, and buccinator branches from the facial artery. Within the fat pad, a network of small arterioles and venules are present and care must be taken to avoid disruption of these vessels through overzealous manipulation. The fat pad is multilobular with each lobe enclosed within a thin capsule and attached to adjacent structures by supporting ligaments.



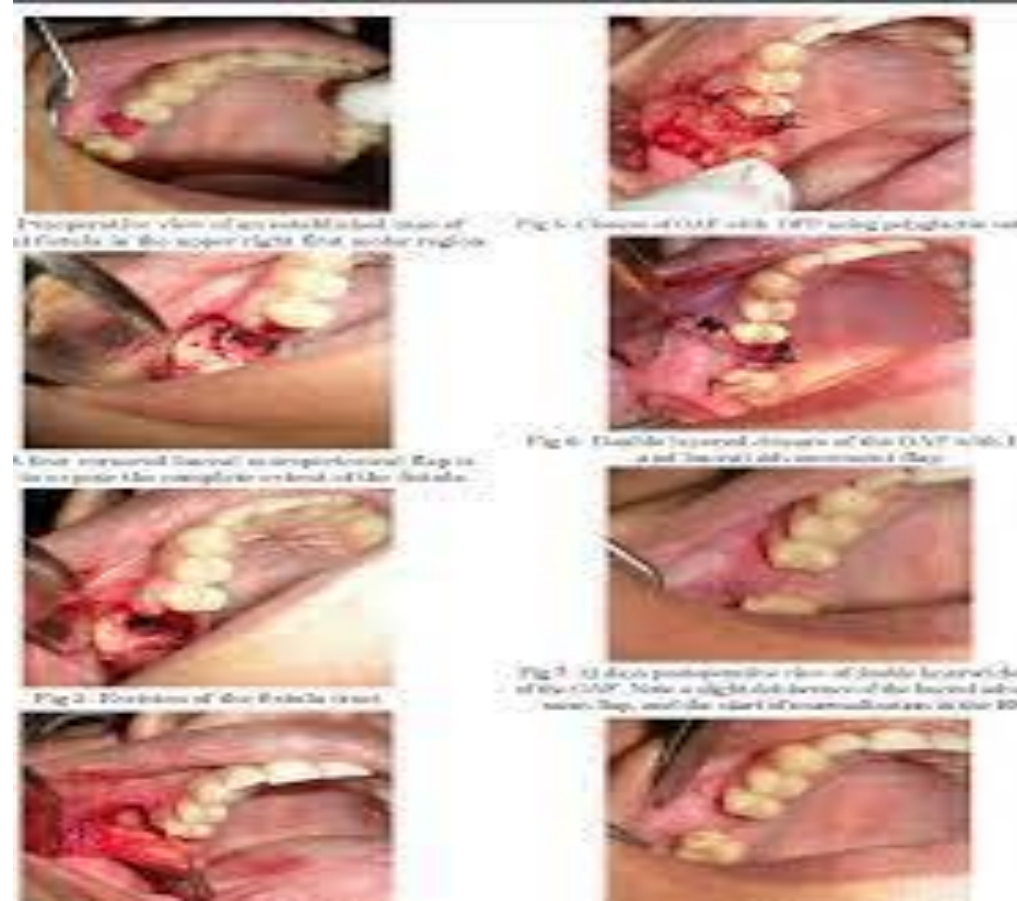
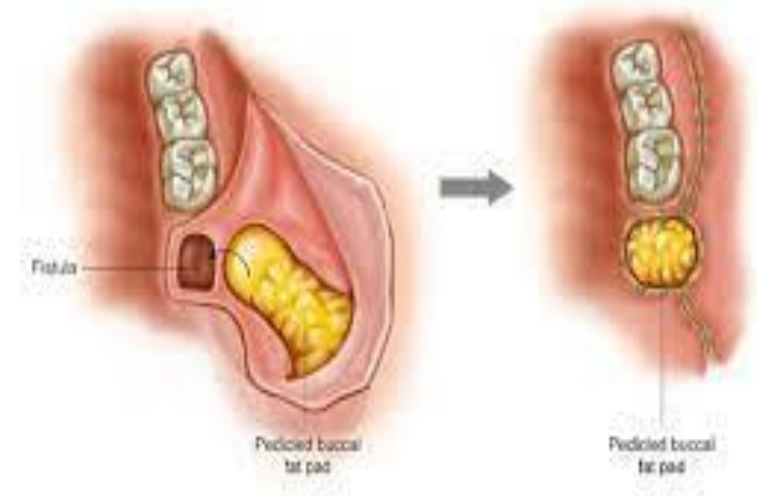
Variations in position of the fat pad occur throughout life accounting for the full facial contours present in infants and the hollowed appearance of the cheeks in the elderly. **However, the volume of the fat pad remains fairly constant and has been estimated to be approximately 10 ml.**

The fat pad is organized into **anterior, intermediate, and posterior lobes**, with four **processes (buccal, temporal, pterygoid, and pterygopalatine)** extending from the posterior lobe.

The different lobes lie between the **buccinator medially, masseter laterally, the ascending ramus of the mandible posteriorly**, and the **zygoma superiorly**. T

The central corpus composed of the anterior and intermediate lobes along with the buccal process of the posterior lobe represent the major components of the buccal fat pad flap (BFPF) used for reconstruction.

The **buccal branches of the facial nerve and the parotid duct are lateral to the fat pad and are usually not encountered during flap development**. If access to the fat pad has not already been created by the ablative procedure, an incision in the **vestibular sulcus distal to the maxillary tuberosity through the periosteum will expose the buccal fat pad**. After widening the access to prevent constriction of the BFPF pedicle, the flap is placed under tension at its leading edge while blunt dissection mobilizes the flap by dividing the supporting ligaments. **Between and 9 cm of length may be achieved and the flap is sewn to the defect margins either with sutures to a soft tissue margin or tied to holes drilled through the bony margins.**

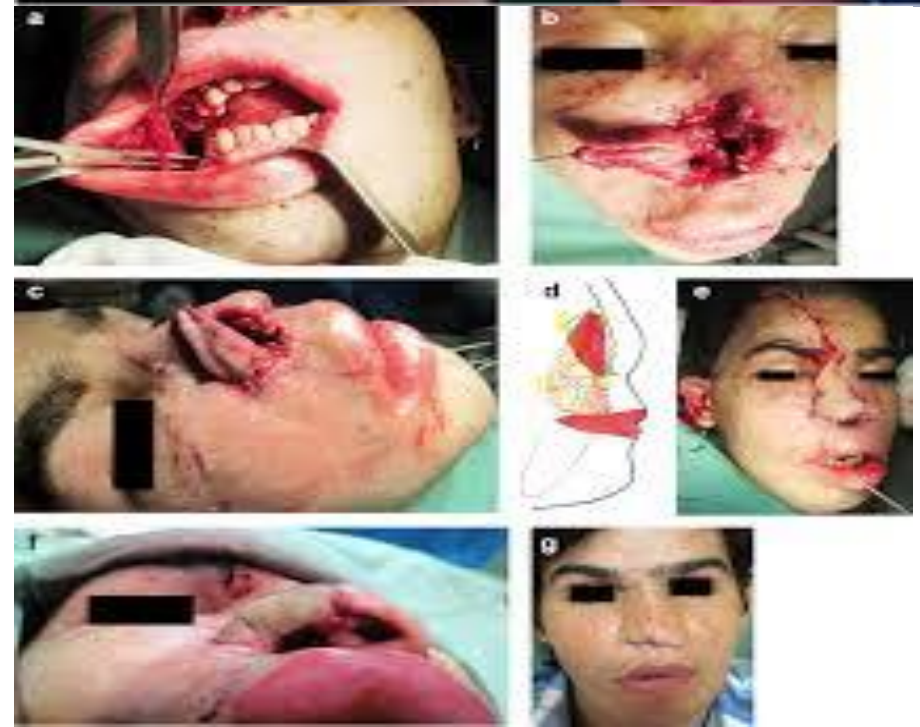
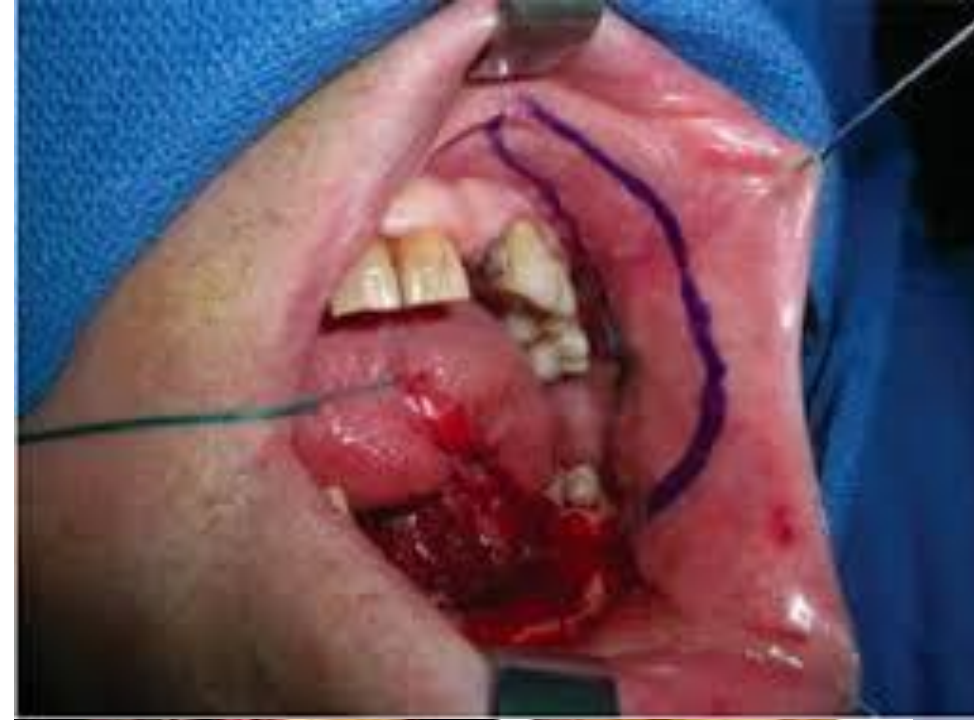
The BFPP is a highly versatile surgical tool in maxillary reconstruction and can be used to close class I and IIa maxillectomy defects, oro-antral communications, and lateral wall and palatal voids. However, defects larger than 4 cm in diameter, or in radiated fields, may not be suitable for reconstruction with a BFPP.

Although the buccal fat pad has been used as a vascularized bed to cover a bone graft during maxillary reconstruction, **it is not sufficiently reliable for this purpose**. The BFPP technique is associated with low morbidity and produces **minimal contour changes and facial asymmetry**. The only problem is obliteration of the **maxillary vestibule in the region where the flap traverses from the cheek to the maxilla, and this may compromise stability of**

□ **Facial Artery Musculomucosal Flap:** An intraoral cheek flap. In 1992, Pribaz introduced the facial artery musculomucosal flap (FAMM). This axial flap using the facial vessels and can be raised either as a superiorly or inferiorly based flap. In raising the flap, the mucosa and submucosa, the buccinator muscle and a slice of the orbicularis oris are incorporated into the flap since the vessels are lateral to these structures. The flap can be used to reconstruct the palate, nasal septum, floor of the mouth, lips, as well as the tongue and alveolus. The flap can be up to 3-cm-wide and the full buccal height can be harvested. The Stensen duct of the parotid gland must be avoided and dentition in the arc of the rotation can serve as a contraindication.

No external visible scars and a mucosal surface represent favourable characteristics in oral reconstruction.



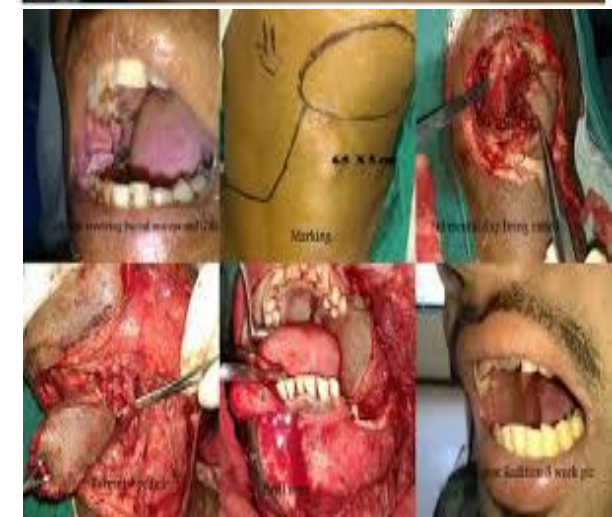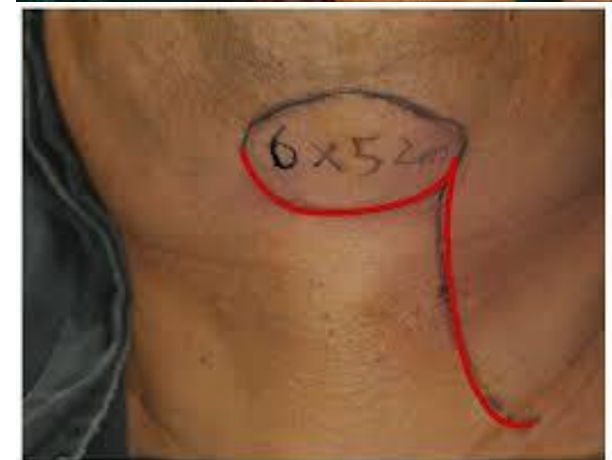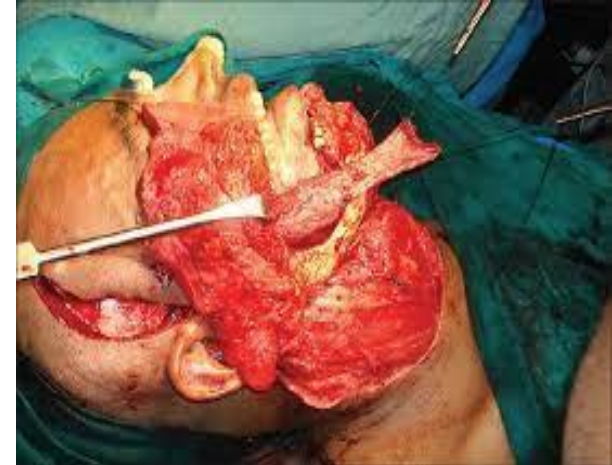□ **Temporalis muscle flap:** The external cheek, orbital exenteration, as well as maxillary and oral defects can be reconstructed using this flap.

The temporal muscle elevates the mandible from its origin in the temporalis line and the infratemporal crest for insertion into the coronoid process. The temporal fascia consists of the superficial temporoparietal and deep temporal fascia, further divided into superficial and deep layers.

The muscle lies beneath the deep temporal fascia. These layers feature their own vasculature, with the superficial temporal fascia stemming from the superficial

prosthesis temporal vessels and the temporal muscle stemming from the deep temporal arteries originating at the internal maxillary artery. When harvesting the muscle flap, temporary removal of the zygomatic arch provides additional length to the flap. The flap measures from 12- to 16-cm-long and 0.5- to 1-cm-thick. Major drawbacks include a risk of injury to the facial nerve, postoperative trismus and temporal hollowing.

□ **Submental Flap:** In 1993, Martin et al. presented the submental flap, a perforator or pedicled cutaneous flap from the submental region based on the submental branch of the facial artery. This flap features good colour match, good reach to the anterior mouth and the donor site is directly closed; typically, it offers an abundance of tissue, particularly in elderly patients. The skin paddle can reach up to 10 cm by 16 cm; the pedicle reaches up to 5 cm and the platysma muscle, a part of the mylohyoid, as well as the anterior digastricus muscle are included. The submental flap is also applicable in facial vessels proximally divided through a reverse flow, and can also be used as a free flap. The submental flap is ideal for reconstructing bearded areas in men.

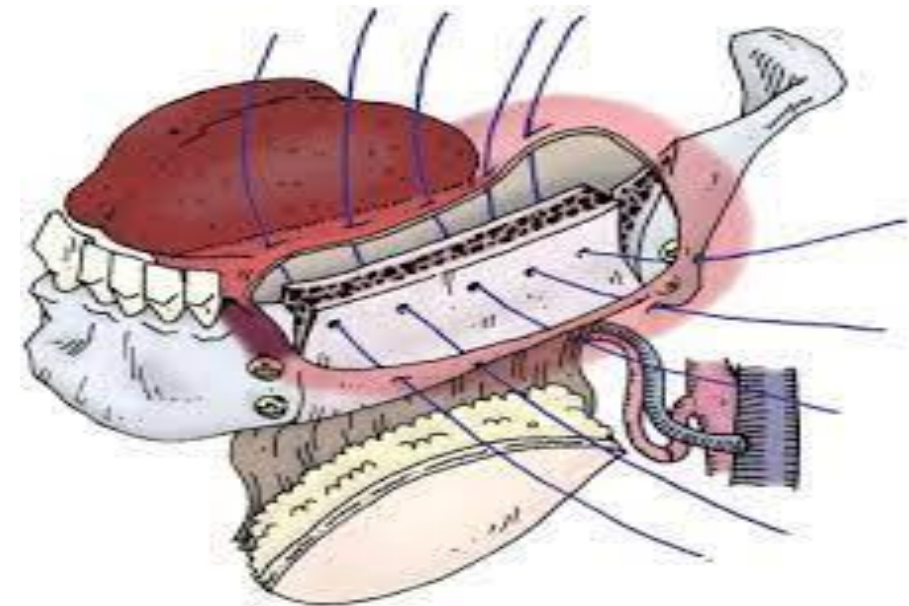
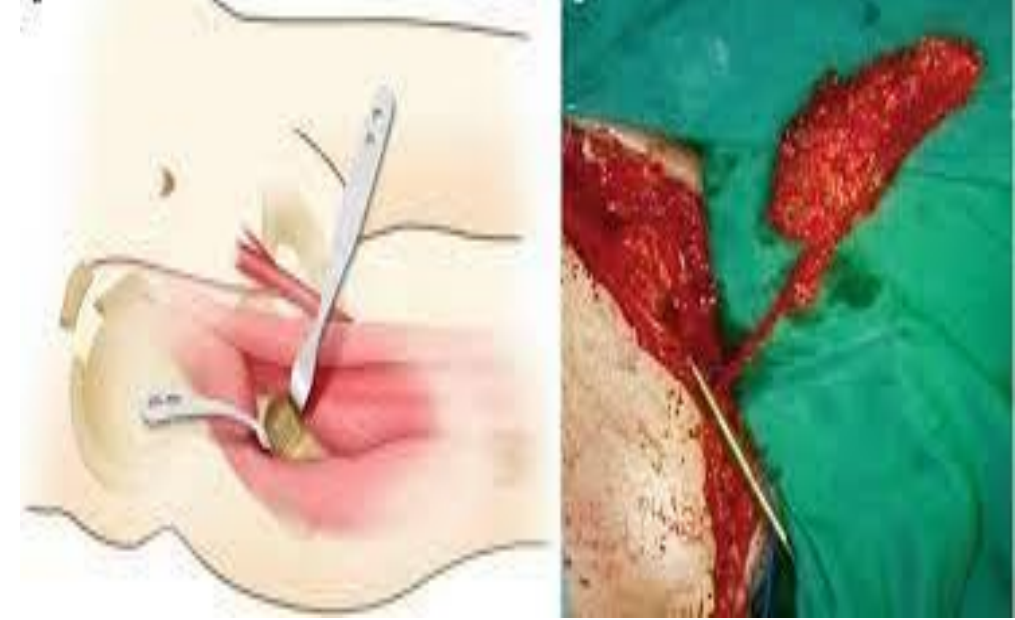


Vascularized Iliac Crest Grafts (example on free composite flap):

Vascularized iliac crest flap is one of the principle flaps for bony reconstruction of head and neck defects following resection of benign or malignant conditions of the mandible and maxilla. This flap undoubtedly provides the best bone stock for orofacial reconstruction and is ideal where prosthetic rehabilitation with dental implants is desired. The flap is based on the deep circumflex iliac artery (DCIA), which originates from the external iliac artery and gives off branches into the muscle, bone, and skin. The flap is invariably taken with a part of internal oblique muscle; however, a skin component can be included, but this is unpopular due to its excessive bulk and also unpredictability of perforator blood supply. Further developments have seen raising of this flap as bone only or skin and bone perforator flaps.

Due to the abundance of bone and the various possibilities for designing the flap it is suitable for a variety of defects arising from resection of tumors of the mandible and maxilla.

It is particularly suited for reconstruction of **segmental mandibular defects in dentate patients**, augment an atrophied mandible to restore masticatory function, allowing for insertion of dental implants. It has been found to be useful for bone-only reconstruction of lateral defects of 5 cm up to hemi-mandibular defects following resection of primary bone tumors, such as ameloblastoma in young patients. Other bone-only defects resulting from conditions (such as, trauma and chronic non-unions) may also be suitably reconstructed with iliac crest flaps.



For defects extending outside the maxillary alveolus and involving the inferior orbital rim and floor, the DCIA flap provides excellent bone height and width necessary for facial harmony. When there is a large partial glossectomy defect with an anterior mandible defect, the skin paddle can be used to reconstruct tongue with internal oblique used as floor of mouth. The flap can also be utilized to reconstruct through-and-through defects, where the internal oblique muscle is used for intraoral reconstruction and the skin paddle used for external skin. **Contraindications for this flap include a previous iliac crest bone harvest, an inguinal hernia repair or abdominal surgery affecting the harvest site, such as appendectomy. Patients with gait problems are also unsuitable, because this may aggravate their existing problem.**

Obesity makes the operation very challenging and possibly unsuitable skin component; however, the flap can be raised if only including the bone and muscle.

THANK YOU

